

## Immunoexpression of progesterone receptor, epithelial growth factor receptor and galectin-3 in uterine smooth muscle tumors

Mervat M. Soltan<sup>1,2</sup>, Abdelkader Mohammed Albasri<sup>1</sup>, Maha K. Eldosouky<sup>3,4\*</sup>, Hanan S. Abdelhamid<sup>5</sup>

<sup>1</sup>Department of Pathology, Faculty of Medicine, Taibah University, Almadina, KSA

<sup>2</sup>Department of Pathology, National Liver Institute, Menoufia University, Menoufia, Egypt

<sup>3</sup>Department of Anatomy, Faculty of Medicine, Taibah University, Almadina, KSA

<sup>4</sup>Department of Anatomy, Faculty of Medicine, Alminia University, Alminia, Egypt

<sup>5</sup>Department of Pathology, Faculty of Medicine, Cairo University, Cairo, Egypt

Correspondence to: mahadesouky7@gmail.com

Received January 21, 2018; Accepted April 15, 2018; Published April 30, 2018

Doi: <http://dx.doi.org/10.14715/cmb/2018.64.5.2>

Copyright: © 2018 by the C.M.B. Association. All rights reserved.

**Abstract:** Uterine smooth muscle tumors constitute a spectrum of neoplasms. Diagnosis of leiomyomas (LMs) is usually straight forwards; however, atypical leiomyomas (ALMs) and smooth muscle tumors of uncertain malignant potential (STUMPs) have overlapping features and need to be distinguished from leiomyosarcoma. To evaluate progesterone receptor (PR), epithelial growth factor receptor (EGF-R), and galectin-3 expression in LMs, ALMs, STUMPs, and leiomyosarcomas and to assess their possible role in differentiating those tumors. Immunoexpression of EGF-R, PR, and galectin-3 were studied in 44 cases of uterine smooth muscle tumors through retrospective study. Studied cases included 20 LM, 9 ALM, 5 STUMP, and 10 leiomyosarcomas. A semiquantitative score was used to evaluate immunohistochemical staining. EGF-R overexpression was detected in leiomyosarcomas while a lack of or reduced EGF-R expression was observed in the nonsarcomatous group (LMs, ALMs, and STUMPs) with a highly significant difference. On the contrary, there was weak or negative PR staining in leiomyosarcomas compared to intense PR expression in the nonsarcomatous group with a highly significant difference. Meanwhile, galectin-3 was downregulated in leiomyosarcomas compared to the nonsarcomatous group with a significant difference. Correlation analysis revealed negative correlation between EGF-R and PR expression with significant statistical results while correlation of galectin-3 with EGF-R and PR showed insignificant statistical results. Immunoexpression of EGF-R, PR, and galectin-3 could help differentiate challenging cases of uterine smooth muscle tumors. Further studies are recommended to investigate interactions between EGF-R, PR, and galectin-3 and to plan new therapeutic strategies.

**Key words:** Leiomyoma. Receptor; Progesterone; Galectin 3.

### Introduction

Uterine smooth muscle tumors (SMTs) are common gynecologic neoplasms (1). With regard to mitotic rate, tumor necrosis, and degree of nuclear atypia, uterine SMTs are divided into leiomyomas (LMs), mitotically active leiomyomas, atypical or symplastic leiomyomas, smooth muscle tumors of uncertain malignant potential (STUMPs), and leiomyosarcomas (LMSs) (2). Some LM cases, though benign, for example cellular leiomyoma, atypical leiomyoma (leiomyoma with bizarre nuclei) (ALM), and mitotically active leiomyoma, may exhibit unusual morphological, sometimes overlapping, features with leiomyosarcoma (3, 4). Uterine smooth muscle tumors of uncertain malignant potential (STUMPs) are uncommon neoplasms with uncertain biological behavior. This category requires accurate interpretation, as a wrong diagnosis leads to different therapeutic and follow-up procedures (3). Variations in interpretation and subjective identifications of some histological features (proliferative activity measured by presence or absence of mitotic figures and its number, presence or absence of necrosis and its type) have resulted in introducing potential diverse diagnostic criteria for uterine SMTs (4). Thus, it would be valuable to mini-

mize misinterpretation and develop adjunct methods to evaluate problematic cases and to differentiate equivocal cases of leiomyoma from STUMP and leiomyosarcoma for the optimal management of patients (4). Growth and development of uterine SMTs have been shown to be crucially influenced by steroid hormones and growth factors and/or their receptors (5, 6). It is generally accepted that leiomyomas grow hormone dependent, with estrogen receptor (ER) and progesterone receptor (PR) expression being reported in literature (7,8). Regulation of growth factor gene expression may be mediated by estrogen and progesterone, and this regulation changes other genes' transcription (9). Regional production of growth factors is said to mediate steroids' mitogenic action on their target organs through paracrine and/or autocrine mechanisms (6). Epidermal growth factor receptor (EGF-R) is a transmembrane cell surface receptor and is one of four members of the ErbB receptor family. EGF-R is implicated in the pathogenesis of several disease processes, such as oncogenesis, and is linked to poor prognosis in several malignant neoplasms (10). Abnormal EGF-R expression was detected in many tumor types, and anti-EGFR antibodies have been recently used as a part of targeted therapy in patients with abnormal EGF-R expression (11). Galectins can regu-

late epithelial morphogenesis and signal transduction (12). Galectin-3 is usually present in the nucleus and cytoplasm and could be found in extracellular matrix in particular conditions (13,14). Galectin-3 was assumed to have a correlation with tumor progression and distant spread (15, 16). Both galectin-3 nuclear and cytoplasmic expression were correlated with vascular invasion (14). Galectin-3 expression in malignant tumors was assumed to have a dynamic state ranging from low to high levels according to stage of invasion and ending in low levels at the final stage of metastasis facilitating tumor progress and metastasis. However, galectin-3 may show anticancer properties (17, 18). Therefore, galectin-3 overexpression was demonstrated in many types of malignant neoplasms and was correlated with tumor progress and metastasis, yet galectin-3 downregulation was also correlated with malignant transformation in other malignant tumor types (17). Abnormal galectin-3 expression and its prognostic role seem to be dependent on tumor type (19). Increased galectin-3 expression was associated with fibrosis and malignancy in thyroid nodules (20). Galectin-3 overexpression was correlated with poor outcome in some tumors, such as colon carcinoma, and prostatic carcinoma, while it was linked with favorable outcome in others, such as gastric carcinoma. No or conflicting results are available about many other tumor types (12, 14, 19). Galectins have reliable capacity for distinguishing leiomyomas from leiomyosarcomas (21). The ErbB protein family is associated with genes like galectin-1 and galectin-3, which are involved in cell-matrix interactions (22, 23). EGF-R and galectin-3 immunoreactivity, together with other several markers, could help recognize high risk serous ovarian carcinomas (10). Cui *et al* (24), reported that knockdown of galectin-3 in esophageal squamous cancer cells (which show EGF-R overexpression) lead to enhancement of the gefitinib (an EGFR-tyrosine kinase inhibitor) therapeutic effect on these tumor cells, as lack of galectin-3 impairs the EGF-R endocytosis. On the other hand, total lack of galectin-3 strongly increased EGF-R surface expression in pancreatic cancer cells (13, 14). Galectin-3 and galectin-1 mediate production and metabolism of progesterone in the luteal cells of the mouse's ovary (25). Galectin-3 expression was found to be upregulated by progesterone in endometrial cells leading to a lower rate of apoptosis (26, 27). Therefore, The final diagnosis of uterine SMTs may be supported by immunohistochemical studies of some steroid hormone receptors, oncoproteins, and galectin (1, 28). The aim of this study was to evaluate pathological features of uterine SMTs and to correlate immunohistochemical evaluation for diagnostic and therapeutic purposes.

## Materials and Methods

### Patients

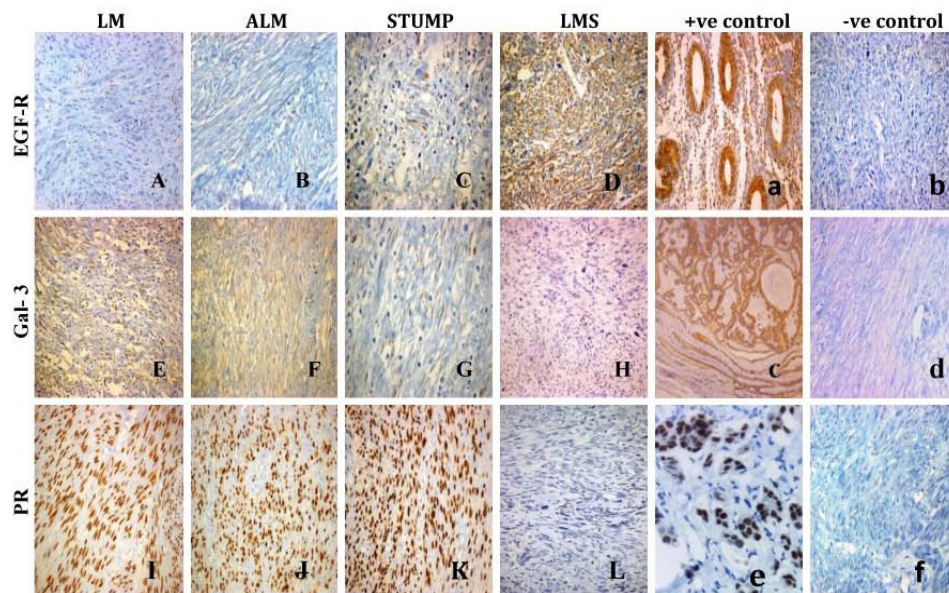
This retrospective study included 44 cases of uterine smooth muscle tumors. They were retrieved from the archives of the pathology departments of Three University teaching hospitals Al- Madina Maternity and Children's Hospital, Saudi Arabia; Faculty of Medicine, Cairo University, Egypt; and Faculty of Medicine, Al Minia University, Egypt—acquired from 2013 till 2015. The study was approved by the local ethics committee

and was performed in accordance with the Declaration of Helsinki and Good Clinical Practice Guidelines.

### Pathological diagnosis and immunohistochemical staining

The specimens were anonymous for confidentiality and replaced by numbers. Specimens with marked degeneration or necrosis were excluded. The main limitation was the relatively small number of leiomyosarcoma and STUMP cases compared to leiomyoma cases in the same time period. Accordingly, cases included leiomyomas ( $n = 20$ ), atypical leiomyomas ( $n = 9$ ), STUMPs ( $n = 5$ ), and leiomyosarcomas ( $n = 10$ ). The study was carried out with full local ethics approval. Paraffin blocks of selected cases were cut at 5  $\mu\text{m}$  thickness, mounted on glass microslides, and processed for hematoxylin and eosin staining. The cases were reviewed blindly by two independent histopathologists and assigned for histological diagnosis according to the following criteria: tumors with 10 or more mitotic figures (MF)/10 high-power fields (HPF) and diffuse moderate to severe atypia were diagnosed as leiomyosarcomas. Also, any tumor showing coagulative necrosis with diffuse moderate to severe atypia and any level of MF/10 HPF or with none to mild atypia and 10 or more MF/ 10 HPF was diagnosed as leiomyosarcoma. Tumors with less than 10 MF/10 HPF and diffuse moderate to severe atypia were diagnosed as STUMPs. Tumors with less than 5 MF/10 HPF and focal or diffuse moderate to severe atypia were diagnosed as atypical leiomyomas. Tumors without atypia and less than 5 MF/10 HPF were diagnosed as leiomyomas (29).

For immunohistochemical staining, tissue sections were cut from paraffin blocks at 3-5  $\mu\text{m}$  and mounted onto poly-L-lysine-coated slides. *Deparaffinization* was done in xylene for 15 min followed by *rehydration* in descending grades of ethanol (100%,90%, 70%, 50%) followed by washing twice in phosphate buffer saline (PBS) (pH 7.6). *Endogenous peroxidase activity* was inhibited by incubation with 3% hydrogen peroxide for 5 minutes followed by washing twice in PBS (pH 7.6). *For antigen retrieval*, slides were immersed in 10 mm sodium citrate buffer pH (6.0) and were twice pretreated by microwaving (800 W) for 4 and then 8 minutes, after cooling, the sections were washed twice in PBS (pH 7.6). *Protein blocking* was performed by incubating tissue sections with diluted normal serum (150  $\mu\text{L}$  horse serum in 10 ml PBS; Vector Laboratories, Burlingame, CA, USA) for 20 minutes at room temperature to prevent nonspecific binding of the primary antibodies. *Immunostaining* was performed using ready-to-use antibodies, rabbit monoclonal antiprogestosterone receptor (PR) (1E2) antibody (Ventana, CA, USA, Cat # 790-2223) incubated for 16 minutes at 36°C, rabbit monoclonal anti-EGFR L858R (SP125) antibody (Ventana, CA, USA, Cat # 790-4649) incubated for 24 minutes at 36°C, and mouse monoclonal anti-galectin-3 (9C4) antibody (Cell Marquo, CA, USA, Cat #760-4256) incubated for 32 minutes at 37°C. *Reactivity* was visualized using Ventana Ultra View Universal DAB detection kits (ready-to-use) according to the manufacturer's instructions. Sections were *counterstained* with Mayer's acidic haematoxylin for 1-2 minutes and then *dehydrated* in ascending ethanol grades (70%, 80%, 90%, 100%).



**Figure 1.** Photomicrographs of the currently studied antibodies' expression in uterine smooth muscles tumor cases. Leiomyoma showing negative immunoreactivity to EGF-R ( $\times 200$ ) (A); atypical leiomyoma showing negative immunoreactivity to EGF-R ( $\times 200$ ) (B); STUMP showing weak cytoplasmic immunoreactivity to EGF-R ( $\times 400$ ) (C); leiomyosarcoma showing strong cytoplasmic immunoreactivity to EGF-R ( $\times 400$ ) (D); lung adenocarcinoma as a positive control for EGF-R ( $\times 400$ ) (a); LMS as a negative control for EGF-R ( $\times 200$ ) (b); leiomyoma showing strong cytoplasmic immunoreactivity to galectin-3 ( $\times 200$ ) (E); atypical leiomyoma showing strong cytoplasmic immunoreactivity to galectin-3 ( $\times 200$ ) (F); STUMP showing weak cytoplasmic immunoreactivity to galectin-3 ( $\times 400$ ) (G); leiomyosarcoma showing negative immunoreactivity to galectin-3 ( $\times 200$ ) (H); thyroid papillary carcinoma as a positive control for galectin-3 ( $\times 400$ ) (c); leiomyoma as a negative control for galectin-3 ( $\times 200$ ) (d); leiomyoma showing strong nuclear immunoreactivity to PR ( $\times 400$ ) (I); atypical leiomyoma showing strong nuclear immunoreactivity to PR ( $\times 400$ ) (J); STUMP showing strong nuclear immunoreactivity to PR ( $\times 400$ ) (K); and leiomyosarcoma showing negative immunoreactivity to PR ( $\times 200$ ) (L); breast carcinoma as a positive control for PR ( $\times 400$ ) (e); leiomyoma as a negative control for PR ( $\times 200$ ) (f).

After *xylene* treatment, the slides were *mounted* and *cover glasses* were put onto them. Suitable negative and positive controls were performed. Negative control was done by using PBS instead of the primary antibody. Positive control was done using sections of positive breast carcinoma for antiprogestosterone receptor (PR) (1E2), sections from lung adenocarcinoma for anti-EGFR L858R (SP125), and sections from papillary thyroid carcinoma for anti-galectin-3 (9C4).

Anti-PR, anti-EGFR, and anti-galectin-3 immunohistochemical staining results were evaluated using the semi-quantitative International Remmele Score (IRS) (30, 31). The IRS scoring consists of optical staining intensity and distribution or percentage of positively stained cells. The optical staining intensity was graded as 0 = no, 1 = weak, 2 = moderate, and 3 = strong. Distribution or percentage of positively stained cells was scored as follows: 0 = no staining, 1 = <10% of cells, 2 = 11%–50% of cells, 3 = 51%–80% of cells, and 4 =>81% of cells. Tissue sections were examined by two independent observers, and the images were captured using an image analyzer (Leica Q Win standard digital camera CH-9435 DFC 290, coupled with photomicroscope, Germany).

### Statistical analysis

The nonparametric Mann-Whitney U test was used to evaluate the results. Estimation of correlations between EGF-R, PR, and galectin-3 was done using the nonparametric Spearman correlation coefficient (IBM SPSS, New York, NY, USA). Results were considered statistically significant with P values of less than 0.05 and highly significant with P values of less than 0.01.

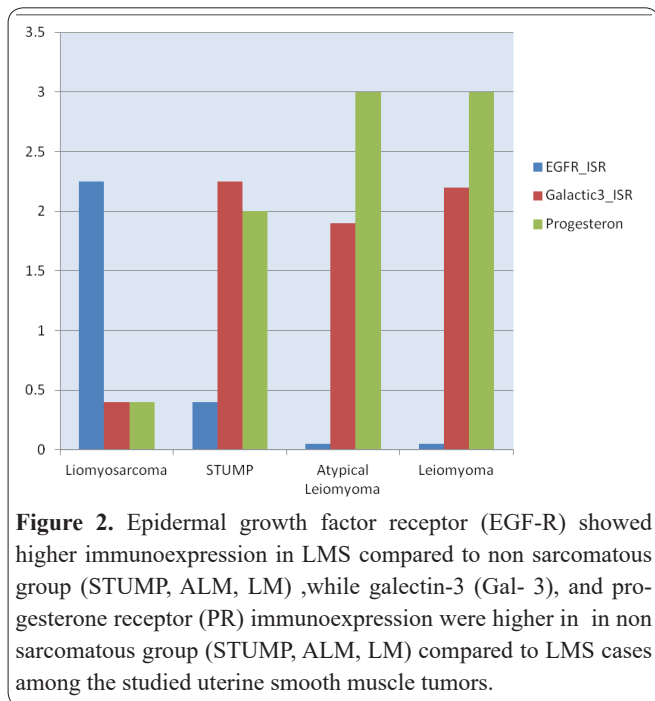
## Results

### Immunostaining histological examination of uterine smooth muscle tumors

EGF-R in all LMS cases showed strong cytoplasmic expression, (mean IRS =  $7.40 \pm 3.02$ ; Figure 1.D) while negative EGF-R expression was noted in 18 out of 20 LM cases (mean IRS =  $0.040 \pm 0.69$ ; Figure 1.A). The ALMs (Figure 1.B) and STUMPs (Figure 1.C) showed negative or weak EGF-R expression (IRS was 1+ or 0) with a mean IRS of  $0.40 \pm 0.548$  for STUPMs and  $0.05 \pm 0.224$  for ALMs. The EGF-R expression showed a highly significant difference between the leiomyosarcoma group (mean IRS =  $7.40 \pm 3.02$ ) and the nonsarcomatous group (LMs, ALMs, and STUMPs) (mean IRS =  $0.08 \pm 0.28$ ;  $p < 0.001$ ; Table 1 and Figure 2). On the contrary, the nonsarcomatous group (LMs, ALMs, and STUMPs) showed a strong PR nuclear expression (mean IRS =  $2.85 \pm 0.500$ ) (Figure 1.I, 1.J, 1.K) while the LMSs were either negative (Figure 1. L) or weakly stained for PR, and one case showed moderate nuclear PR expression (mean IRS =  $0.40 \pm 0.699$ ). The PR expression showed a highly significant difference between the nonsarcomatous group and the LMSs ( $p < 0.001$ ) and among LMSs in comparison to each LM, ALM, and STUMP cases ( $p < 0.001$ ; Table 1 and Figure 2). Leiomyosarcomas revealed downregulated cytoplasmic galectin-3 (Gal-3) expression (mean IRS =  $0.20 \pm 0.42$ ; Figure 1.H) compared to the LMs (mean IRS =  $6.40 \pm 3.05$ ). There was a significant difference between LMSs and the nonsarcomatous group LMs, ALMs, and STUMPs (Figure 1.E, 1.F, 1.G), ( $p < 0.01$ ; Table 1 and Figure 2).

**Table 1.** Immunoeexpression of epidermal growth factor receptor (EGF-R), progesterone receptor (PR), and galectin-3 (Gal-3) in studied uterine smooth muscle tumors.

	Leiomyosarcoma	Nonsarcomatous group	P value
<b>EGF-R</b>	7.40 ± 3.02	0.08± 0.28	0.001
<b>PR</b>	0.40 ± 0.699	2.85 ± 0.500	0.001
<b>Gal-3</b>	0.20 ± 0.42	6.05 ± 2.99	0.01



**Figure 2.** Epidermal growth factor receptor (EGF-R) showed higher immunoeexpression in LMS compared to non sarcomatous group (STUMP, ALM, LM), while galectin-3 (Gal-3), and progesterone receptor (PR) immunoeexpression were higher in non sarcomatous group (STUMP, ALM, LM) compared to LMS cases among the studied uterine smooth muscle tumors.

**Correlation analysis**

Correlation analysis between the nonsarcomatous cases and leiomyosarcoma cases revealed a significant negative correlation between EGF-R and PR expression (Spearman  $r = -0.481$  in leiomyosarcoma cases and  $-0.623$  in nonsarcomatous cases,  $p = 0.05$  and  $0.000$ , respectively; Table 2). Further subgroup analysis within the tumoral cases revealed that EGF-R correlated positively with Gal-3 expression in the leiomyosarcoma group (Spearman  $r = 0.089$ ,  $p = 0.808$ ) and negatively correlated in the nonsarcomatous group (Spearman  $r = -0.135$ ,  $p = 0.446$ ); both were statistically insignificant (table, 3). Progesterone receptor expression correlated positively with Gal-3 expression in the leiomyosarcoma group (Spearman  $r = 0.323$ ,  $p = 0.363$ ) and negatively

**Table 2.** Correlation between progesterone receptor (PR) and epidermal growth factor receptor (EGF-R) immunoeexpression in studied uterine smooth muscle tumors.

	PR	EGF-R	r	P value
<b>Leiomyosarcoma</b>	0.40 ± 0.699	7.40 ± 3.02	- 0.481	0.05
<b>Nonsarcomatous group</b>	2.85 ± 0.500	0.08 ± 0.28	- 0.623	0.000

**Table 3.** Correlation between epidermal growth factor receptor (EGF-R) and galectin-3 (Gal-3) immunoeexpression in studied uterine smooth muscle tumors.

	EGF-R	Gal-3	r	P value
<b>Leiomyosarcoma</b>	7.40 ± 3.02	0.20 ± 0.42	0.089	0.808
<b>Nonsarcomatous group</b>	0.08 ± 0.28	6.05 ± 2.99	-0.135	0.446

**Table 4.** Correlation between progesterone receptor (PR) and galectin-3 (Gal-3) immunoeexpression in studied uterine smooth muscle tumors.

	PR	Gal-3	r	P value
<b>Leiomyosarcoma</b>	0.40 ± 0.69	0.20 ± 0.42	0.323	0.363
<b>Nonsarcomatous group</b>	2.85 ± 0.500	6.05 ± 2.99	- 0.150	0.397

correlated in the nonsarcomatous group (Spearman=  $r = -0.150$ ,  $p = 0.397$ ); both were statistically insignificant (Table 4).

**Discussion**

As standard chemotherapeutic regimens have been of limited value in uterine sarcomas; researchers need to develop new therapeutic agents via investigating biological factors (32). In the present study, expression of PR, EGF-R and galectine-3 was examined through immunohistochemistry in patients with LMs, ALMs, STUMPs, and LMSs. Regarding the steroid receptor status of uterine smooth muscle tumors, Hewedi et al (1) demonstrated intense PR expression in 100% of leiomyomas and atypical leiomyomas, with marked decrease in leiomyosarcomas. In addition, progesterone receptors were reported to be expressed in 100% of leiomyomas and in 96% of atypical leiomyomas compared to 47% of leiomyosarcomas (33). Our findings were consistent with these results, as there was increased nuclear PR immunoreactivity in the nonsarcomatous group compared to the leiomyosarcoma group with significant statistical relation. Regarding EGF-R expression, we observed immunohistochemical cytoplasmic staining for EGF-R, which was more intense with increased numbers of positively staining cells in the leiomyosarcomas compared to the nonsarcomatous uterine smooth muscle tumors with a highly significant statistical relation. Supporting our findings, Sanci et al (32) documented mild to moderate EGF-R expression in leiomyoma cases and moderate EGF-R expression in cellular leiomyoma cases compared to marked EGF-R expression in leiomyosarcoma cases. Nevertheless, Anderson et al (30) demonstrated no difference between EGF-R expression in uterine leiomyosarcoma and leiomyoma cases. This report revealed decreased cytoplasmic galectin-3 immunoreactivity in the leiomyosarcoma group compared to the nonsarcomatous group with significant difference between the two groups. These findings were consistent with that of Schwarz et al (34), who found that galectin-3 binding sites in leiomyosarcomas are of weaker concentration than in leiomyomas. Additionally, galectin-3 downregulation was observed in leiomyosarcoma cases compared to leiomyoma cases and myometrium samples (35). The current findings showed a significant negative correlation between EGF-R and PR in leiomyosarcoma cases and nonsarcomatous cases. These findings were in agreement with that of Lusby et al (36), who demonstrated that uterine leiomyosarcoma cases compared to non-neoplastic controls, including myometrium and leiomyoma cases, exhibited loss of PR expression and EGF-R overexpression. In contrast, other report demonstrated that EGF-R levels showed neither menstrual cycle variation nor a differential level of ex-

pression in leiomyoma and myometrium (9). This might be caused by variations in antibody content. Additionally, immunocytochemical analysis demonstrated that the treatment with progesterone did not augment EGF-R expression in the leiomyoma cells compared to that in untreated leiomyoma cells (37). Weissenbacher *et al.* (28) reported that activated EGF-R through phosphorylation showed a negative correlation between pEGFR-Y845 and galectin-3 expression in leiomyomas and leiomyosarcomas but not in myometrial samples. The current study found that EGF-R showed a positive correlation with galectin-3 expression in leiomyosarcoma cases and negative correlation with galectin-3 expression in nonsarcomatous group cases with insignificant statistical relation. This could be explained by the difference between EGF-R used in Weissenbacher's study (28), which was in an activated form from the one used in the present study. Also, this could be due to a small sample size in our study raising the need for further study on larger case series. To the best of our knowledge, this is the first study to correlate progesterone expression with galectin-3 expression in uterine smooth muscle tumors except for a study by Kayser *et al.* (21), who examined several antibodies' expression including progesterone receptor and galectin-3 expression in 10 cases of benign metastasizing leiomyoma and found strong progesterone receptor expression in 70% of cases and moderate galectin-3 expression in 90% of cases. We reported a positive correlation of progesterone receptor with galectin-3 in leiomyosarcoma cases and a negative correlation with galectin-3 in nonsarcomatous group cases with insignificant statistical relation. In conclusion, the present findings are very promising in distinguishing leiomyosarcomas from other nonsarcomatous uterine smooth muscle tumors, especially those with overlapping features applying multiple immune markers in challenging cases to reach an accurate diagnosis. They should be confirmed by other further studies. Also, it is crucial to further plan for therapeutic strategies and apply progesterone receptor modulators and EGF-R blocking antibodies in these tumors. Additionally, some conflicting results related to galectin-3 expression may be related to racial, genetic variations or differences in methodology.

### Acknowledgements

This work was supported by grand NO .6349/1435 from Deanship of Taibah University, Almadinah Almonawarah, Kingdom of Saudi Arabia.

### Conflict of interest

The authors declare no conflict of interest.

### Author's contribution

The authors contributed equally in this work.

### References

1. Hewedi I H, Radwan N A, Shahs L S. Diagnostic value of progesterone receptor and p53 expression in uterine smooth muscle tumors. *Diagnostic Pathology*. 2012; 7(1):1.
2. Chow K L, Tse K Y, Cheung C L, Wong K W, Cheung A N, Wong R W, *et al.* The mitosis-specific marker phosphohistone-H3 (PHH3) is an independent prognosticator in uterine smooth muscle tumors: An outcome-based study. *Histopathology*. 2017; 70(5): 746-

755.

3. Deodhar K K, Goyal P, Rekhi B, Meno, S, Maheshwari A, Kerkar R, *et al.* Uterine smooth muscle tumors of uncertain malignant potential and atypical leiomyoma: A morphological study of these grey zones with clinical correlation. *Indian J Pathol Microbiol*. 2011; 54 (4): 706-711.
4. Ünver N U, Acikalin M F, Öner Ü, Ciftci E, Ozalp S S, Colak E. Differential expression of P16 and P21 in benign and malignant uterine smooth muscle tumors. *Arch Gynecol Obstet*. 2011; 284(2): 483-490.
5. Marsh E E, Bulun S E. Steroid hormones and leiomyomas. *Obstet Gynecol Clin North Am*. 2006; 33 (1): 59-67.
6. Yu L, Moore A B, Dixon D. Receptor tyrosine kinases and their hormonal regulation in uterine leiomyoma. *Seminars in Reproductive Medicine*. 2010; 28(3): 250-259.
7. Kim J J, Kurita T, Bulun S E. Progesterone action in endometrial cancer, endometriosis, uterine fibroids, and breast cancer. *Endocr Rev*. 2013; 34(1): 130-162.
8. Mozzachio K, Moore A B, Kissling G E, Dixon D. Immunoeexpression of steroid hormone receptors and proliferation markers in uterine leiomyoma and normal myometrial tissues from the miniature pig, *Sus scrofa*. *Toxicol Pathol*. 2016; 44(3):450-457.
9. Sozen I, Arici A. Interactions of cytokines, growth factors, and the extracellular matrix in the cellular biology of uterine leiomyomata. *Fertil Steril*. 2002; 78(1):1-12.
10. Brustmann H. Epidermal growth factor receptor expression in serous ovarian carcinoma: An immunohistochemical study with galectin-3 and cyclin D1 and outcome. *Int J Gynecol Pathol*. 2008; 27(3): 380-389.
11. Khelwatty S, Essapen S, Bagwan I, Green M, Seddon A, Modjtahedi H. The impact of co-expression of wild-type EGFR and its ligands determined by immunohistochemistry for response to treatment with cetuximab in patients with metastatic colorectal cancer. *Oncotarget*. 2017; 8(5):7666-7677.
12. Dondoo T O, Fukumori T, Daizumoto K, Fukawa T, Kohzuki M, Kowada M, *et al.* Galectin-3 Is implicated in tumor progression and resistance to anti-androgen drug through regulation of androgen receptor signaling in prostate cancer. *Anticancer Res*. 2017; 37(1): 125-134.
13. Merlin J, Stechly L, De Beauce S, Monte D, Leteurtre E, Van Seuning I, *et al.* Galectin-3 regulates MUC1 and EGFR cellular distribution and EGFR downstream pathways in pancreatic cancer cells. *Oncogene*. 2011; 30(22): 2514-2525.
14. Song L, Tang J W, Owusu L, Sun M Z, Wu J, Zhang J. Galectin-3 in cancer. *Clin Chim Acta*. 2014; 431: 185-191.
15. Moon B K, Lee Y J, Battle P, Jessup J M, Raz A, Kim H R C. Galectin-3 protects human breast carcinoma cells against nitric oxide-induced apoptosis: Implication of galectin-3 function during metastasis. *The American Journal of Pathology*. 2001; 159(3): 1055-1060.
16. Liu F T, Rabinovich G A. Galectins as modulators of tumour progression. *Nature Reviews Cancer*. 2005; 5(1): 29-41.
17. de Oliveira J T, Ribeiro C, Gärtner F. Role of galectin-3 in cancer metastasis. *Glycobiology Insights*. 2015; 5: 1-13.
18. Ahmed H, AlSadek D M. Galectin-3 as a potential target to prevent cancer metastasis. *Clinical Medicine Insights. Oncology*. 2015; 9: 113-121.
19. Thijssen V L, Heusschen R, Caers J, Griffioen A W. Galectin expression in cancer diagnosis and prognosis: A systematic review. *Biochimica et Biophysica Acta (BBA)-Reviews on Cancer*. 2015; 1855(2): 235-247.
20. Rago T, Scutari M, Loiacono V, Santini F, Tonacchera M, Torregrossa L, *et al.* Low elasticity of thyroid nodules on ultrasound elastography is correlated with malignancy, degree of fibrosis, and high

- expression of galectin-3 and fibronectin-1. *Thyroid*. 2017; 27(1): 103-110.
21. Kayser K, Zink S, Schneider T, Dienemann H, André S, Kaltner H, et al. Benign metastasizing leiomyoma of the uterus: Documentation of clinical, immunohistochemical and lectin-histochemical data of ten cases. *Virchows Arch*. 2000; 437(3): 284-292.
22. Mackay A, Jones C, Dexter T, Silva R. L, Bulmer K, Jones A, et al. cDNA microarray analysis of genes associated with ERBB2 (HER2/neu) overexpression in human mammary luminal epithelial cells. *Oncogene*. 2003; 22(17): 2680-2688.
23. Gupta A. Galectin-3: Forms, functions, and clinical manifestations. In: *Animal Lectins: Form, Function and Clinical Applications*. Gupta G S, Gupta RK, (eds.), Springer, New York Dordrecht London, 2012, p 219.
- Hökert, MR. and Sue T. Regulation of tubulin expression in brain. In: *Cellular and Molecular Biology of the Cytoskeleton*. Shay JW. (ed.), Plenum Press, New York, 1991, in press, accepted: September 10, 1999.
24. Cui G, Cui M, Li Y, Liang Y, Li W, Guo H, et al. Galectin-3 knockdown increases gefitinib sensitivity to the inhibition of EGFR endocytosis in gefitinib-insensitive esophageal squamous cancer cells. *Med Oncol*. 2015; 32(4):124.
25. Nio J, Iwanaga T. Galectins in the mouse ovary: Concomitant expression of galectin-3 and progesterone degradation enzyme (20 $\alpha$ -HSD) in the corpus luteum. *J Histochem Cytochem*. 2007; 55(5): 423-432.
26. Yang H, Lei C, Cheng C, Feng Y, Zhang W, Petracco R G, et al. The antiapoptotic effect of galectin-3 in human endometrial cells under the regulation of estrogen and progesterone. *Biol Reprod*. 2012; 87(2): 39, 1-7.
27. Yang H, Yin J, Ficarrota K, Hsu S H, Zhang W, Cheng C. Aberrant expression and hormonal regulation of galectin-3 in endometriosis women with infertility. *J Endocrinol Invest*. 2016; 39(7): 785-791.
28. Weissenbacher T, Vrekoussis T, Roeder D, Makrigiannakis A, Mayr D, Ditsch N, et al. Analysis of epithelial growth factor-receptor (EGFR) phosphorylation in uterine smooth muscle tumors: Correlation to mucin-1 and galectin-3 expression. *International Journal of Molecular Sciences*. 2013; 14(3): 4783-4792.
29. Zaloudek C J, Hendrickson M R, Soslow R A. Mesenchymal tumors of the uterus. In: Kurman R J, Ellenson L H, Ronnett B M, eds. *Blaustein's pathology of the female genital tract*. 6th ed. New York: Springer. 2011; 453-527.
30. Anderson S E, Nonaka D, Chuai S, Olshen A B, Chi D, Sabbatini P, et al. p53, epidermal growth factor, and platelet -derived growth factor in uterine leiomyosarcoma and leiomyomas. *International Journal of Gynecological Cancer*. 2006; 16(2): 849-853.
31. Jeschke U, Kuhn C, Mylonas I, Schulze S, Friese K, Mayr D, et al. Development and characterization of monoclonal antibodies for the immunohistochemical detection of glycodelin A in decidual, endometrial and gynaecological tumour tissues. *Histopathology*. 2006; 48(4): 394-406.
32. Sanci M, Dikis C, Inan S, Turkoz E, Dicle N, Ispahi C. Immunolocalization of VEGF, VEGF receptors, EGF-R and Ki-67 in leiomyoma, cellular leiomyoma and leiomyosarcoma. *Acta Histochem*. 2011; 113(3): 317-325.
33. Liang Y, Zhang X, Chen X, Lü W. Diagnostic value of progesterone receptor, p16, p53 and pHH3 expression in uterine atypical leiomyoma. *International Journal of Clinical and Experimental Pathology*. 2015; 8(6): 7196-7202.
34. Schwarz G, Rimmelink M, Decaestecker C, Gielen I, Budel V, Burchert M, et al. Galectin fingerprinting in tumor diagnosis: Differential expression of galectin-3 and galectin-3 binding sites, but not galectin-1, in benign vs malignant uterine smooth muscle tumors. *Am J Clin Pathol*. 1999; 111(5): 623-631.
35. Weissenbacher T, Kuhn C, Mayr D, Pavlik R, Friese K, Scholz C, et al. Expression of mucin-1, galectin-1 and galectin-3 in human leiomyosarcoma in comparison to leiomyoma and myometrium. *Anticancer Res*. 2011; 31(2): 451-457.
36. Lusby K, Savannah K B, Demicco E G, Zhang Y, Ghadimi M P, Young E D, et al. Uterine leiomyosarcoma management, outcome, and associated molecular biomarkers: A single institution's experience. *Ann Surg Oncol*. 2013; 20(7): 2364-2372.
37. Maruo T, Matsuo H, Shimomura Y, Kurachi O, Gao Z, Nakago S, et al. Effects of progesterone on growth factor expression in human uterine leiomyoma. *Steroids*. 2003; 68(10): 817-824.