

Investigation of role of vascular endothelial growth factor, Annexin A5 and Apelin by immunohistochemistry method in placenta of preeclampsia patients

Nese Colcimen^{1*}, Gülay Bulut², Ozlem Ergul Erkeç³, Murat Cetin Ragbetli¹¹ Department of Histology and Embryology, Faculty of Medicine, Van Yuzuncu Yil University, Van, Turkey² Department of Pathology, Faculty of Medicine, Van Yuzuncu Yil University, Van, Turkey³ Department of Physiology, Faculty of Medicine, Van Yuzuncu Yil University, Van, Turkey

Correspondence to: colcimennese@hotmail.com

Received August 1, 2017; Accepted November 1, 2017; Published November 30, 2017

Doi: <http://dx.doi.org/10.14715/cmb/2017.63.11.8>

Copyright: © 2017 by the C.M.B. Association. All rights reserved.

Abstract: Preeclampsia is a disease characterized by hypertension and proteinuria occurred after 20 weeks of gestation. Preeclampsia is a major cause of maternal and fetal morbidity and mortality. The pathophysiological mechanism of preeclampsia is not known exactly yet. Preeclampsia endothelial cell dysfunction, associated with inadequate trophoblastic invasion is characterized by abnormal placentation. Vascular endothelial growth factor (VEGF) according to is an angiogenic cytokine, Annexin A5 is among endogenous peptides are both expressed from placental trophoblasts and Apelin is a multifunctional peptide and expressed by placental trophoblasts and endothelial cells. It was aimed to investigate roles of these parameters occurring in preeclampsia and to compare immunoreactivity of them in normal and preeclamptic placenta. In this study, placentas were collected from 20 normotensive pregnant women as controls, 16 mild-preeclamptic pregnant women, and 16 severe preeclamptic women. VEGF, Annexin A5 and Apelin were examined in samples of placenta tissues by streptavidin-biotin-peroxidase complex immunohistochemical methods. Immunoreactivity scores (IRS) were obtained for each parameter. VEGF and Apelin IRS were increased significantly in preeclamptic groups compared with control group ($p < 0.026$, $p < 0.002$ respectively). But Annexin A5 IRS was decreased significantly in preeclamptic groups compared with control group ($p < 0.04$). In correlation with the intensity of disease, increase in VEGF and Apelin, and decrease in Annexin A5 supports roles of hemo-dynamic alterations in fetoplacental circulation and structural alterations in uteroplacental bed occurring in preeclampsia.

Key words: Annexin A5; Apelin; Immunohistochemistry; Placenta; VEGF.

Introduction

Preeclampsia is characterized by hypertension and proteinuria occurred after 20 weeks of gestation. Since 3-8 % of that seen in pregnancy, it is a pregnancy related illness (1). Preeclampsia is a major cause of maternal and fetal morbidity and mortality. The pathophysiological mechanism of preeclampsia is exactly unknown yet. It is currently believed that preeclampsia is a two stage disease. In the first stage, shallow cytotrophoblast invasion of maternal spiral arterioles leads to placental insufficiency. Defective implantation and placentation cause a reduction in uteroplacental perfusion, placental hypoxia and ischemia. Placental ischemia may promote the release of a variety of factors to maternal circulation. In the second stage, these factors initiate a cascade of molecular and cellular events, leading to endothelial and vascular dysfunction (2). Preeclampsia is primarily a disorder of placental dysfunction, leading to systemic endothelial dysfunction with associated vasospasm. In most cases, histopathologic examination of the placenta demonstrates evidence of placental insufficiency with associated abnormalities, such as placental infarction, retroplacental hematoma, blood infiltrates in the villous stroma, immature villi, increased fibrin deposition in perivillous space and inflammatory placental decidual vasculopathy (3). With the help of such pathophysiological data we have studied on three parameters which

may play role in preeclampsia formation stages.. Angiogenic factors such as vascular endothelial growth factor (VEGF), is produced by villous syncytiotrophoblasts and play important roles in uterine vessel remodeling and angiogenesis (4). VEGF is essential for the proliferation of trophoblasts, the development of embryonic vasculature and the growth of maternal and fetal blood vessels in the uterus (5). Apelin, a 36 amino acid peptide, is a multifunctional peptide and expressed by placental trophoblast and endothelial cells which is angiotensin II and bradykinin peptides have blood pressure-modulating effects. The peptide is catabolized by the Angiotensin-converting enzyme-related carboxypeptidase-2 (ACE-2) (6). Apelin exerts a broad range of physiological actions including effects on heart contractility, blood pressure, blood vessel growth, appetite and drinking behavior, pituitary hormone secretion and hypothalamic-pituitary-adrenal axis (7). Annexin A5 (ANXA5), is a multifunctional protein which is expressed from placental trophoblasts and one of its proposed roles is the prevention of thrombosis. The placental anticoagulant protein is a member of the annexins, a family of calcium-dependent phospholipid-binding proteins. ANXA5, anticoagulant effect is due to the ability of this protein to displace coagulation proteins from phospholipid surfaces. ANXA5 is essential for the maintenance of murine placental integrity (3). ANXA5 plays an important role in maintaining the fluidity of intervillous circulation

(8). In our study, we aimed to compare those parameters between normal and preeclamptic placenta for density and immunoreactivity aspect and also intensity of the disease.

Materials and Methods

Study was conducted in Van Yuzuncu Yil University, Faculty of Medicine, Department of Obstetrics and Gynecology on placenta of 52 patients who gave birth there at 3rd trimester. Study was performed following an ethical permission (26/01/2015 and no: 09). 20 placentas were collected from normotensive pregnant women as controls, 16 placentas were collected from mild preeclamptic pregnant women, and 16 placentas were collected from severe preeclamptic women. Diagnosis and classification of severe and mild preeclampsia was done according to the 2002 criteria of American College of obstetrics and Gynecology (ACOG). Twin pregnancy, pre-pregnancy hypertension cases and pregnant with any systemic or local diseases were excluded from study. Placenta full-depth tissue samples measuring 2x2 cm were obtained at the umbilical cord insertion point. Following routine histological processing of tissue samples fixed in 10 % formalin were then sectioned at 5 µm thickness. Then the sections were subjected to streptavidine-biotine-peroxidase complex formation, according to the instructions of the manufacturer. In brief, paraffin-embedded sections were cleared in xylene, rehydrated in a series of ethanol washes. Endogenous peroxidase activity was inhibited with 3% H₂O₂. Antigen retrieval was performed by microwaving sections in citrate buffer (pH: 6). Sections were blocked in PBS (pH: 7.4) for 20 min at room temperature and then protein blockage was performed for inhibition of non-specific staining. Sections were incubated with anti-VEGF, anti-Annexin A5 and Apelin (ab46154 Anti-VEGF, ab113449 Anti-Annexin A5 and ab1817886 Anti-Apelin polyclonal antibodies Abcam, Cambridge, UK) VEGF for 30 min, annexin for 16 hours, Apelin for 20 min, then incubated with biotinylated secondary antibody (UltraVision Detection System; TP-015-HD; Thermo Fisher Scientific, Fremont, CA) for 10 min. Finally streptavidin peroxidase (UltraVision Detection System; TP-015-HD; Ther-

mo Fisher Scientific, Fremont, CA) was added for 10 min, and sections were washed in PBS (ph:7.4) before detection with 3,3-diaminobenzidine (DAB) reagent. After briefly being counterstained with Hemotoxylin and Eosin (H&E) and mounted. The sections were examined under a light microscope at x40 magnification (Olympus Tokyo, Japan). Levels of staining intensity which is Immunoreactivity density was scored from 0.5 to 3+ by the same researcher as 0.5 (Very Weak), 1+ (Weak), 2+ (Mild Degree), 3+ (Strong). Immune reactive cell percentage was obtained via counting 300-500 cells in 10 high power field (HPF). When immunoreactive cells were absent, score was accepted as 0, positive cell scores were accepted as 1 at 10%, 2 at 10-50%, 3 at 51-80 and 4 at above 80%. Immunoreactivity score (IRS) for the immunoreactivity density value immunoreactive cell count score was obtained by multiplying according to the literature (9). Kruskal- Wallis test was used to compare groups' traits. Statistical significance was taken as 5 % for the calculations and SPSS (Ver : 13) statistical software package was used.

Results

32 patients who were diagnosed as severe or mild preeclampsia of 16 patients in each and 20 control subject who did not have any systemic diseases were included. General characteristics of subject are presented in Table 1. There were statistically significant differences among groups for maternal age and gravidity ($p < 0.043$, $p < 0.014$ respectively). Highest values were at mild preeclamptic group. With the severity of disease, comparison of preeclamptic groups with control group revealed that their VEGF and Apelin IRS's were increased and statistically significance was determined ($p < 0.026$, $p < 0.002$ respectively). It was observed that IRS's were attenuated in Annexin A5 in preeclamptic groups however this decrease was significantly it was significant ($p < 0.04$) (Table 2). In general microscopic investigation of tissues were stained with Hematoxylin and Eosin (H&E). The control group had normal histological appearance in the vascular structures of placental tissue and villi of syncytiotrophoblast layer. In preeclamptic groups, the changes occurring in pla-

Table 1. General characteristics of the groups.

	Group	Median	Mean	St.Dev.	Min.	Max.	P
Age (year)	Control (n=20)	23.50	25.20 ^b	6.49	17	38	0.043
	Mild Preeclampsia (n=16)	33.50	31.75 ^a	6.89	18	45	
	Severe Preeclampsia(n=16)	27.50	28.69 ^{ab}	9.38	18	45	
Gravidity	Control (n=20)	1.00	1.85 ^b	1.53	1.00	6.00	0.014
	Mild Preeclampsia (n=16)	3.50	4.06 ^a	2.64	1.00	8.00	
	Severe Preeclampsia (n=16)	1.50	2.19 ^b	1.94	1.00	8.00	

a,b : Different lower cases represent statistically significant differences among the groups ($p < 0.05$).

Table 2. Group mean IRS values for each parameter.

	Control Group (n=20)	Mild Preeclampsia Group (n=16)	Severe Preeclampsia Group (n=16)	P
	Mean ±Standard Deviation	Mean ±Standard Deviation	Mean ±Standard Deviation	
VEGF	4.44±3.63 ^b	5.35±1.81 ^{ab}	7.00±2.37 ^a	0.026
Apelin	0.34 ±0.23 ^b	0.63±0.39 ^b	1.35±1.41 ^a	0.002
Annexin A5	11.25±1.92 ^b	10.38±2.73 ^a	8.875±3.44 ^a	0.04

a,b : Different lower cases in the same row represent statistically significant differences among the groups ($p < 0.05$).

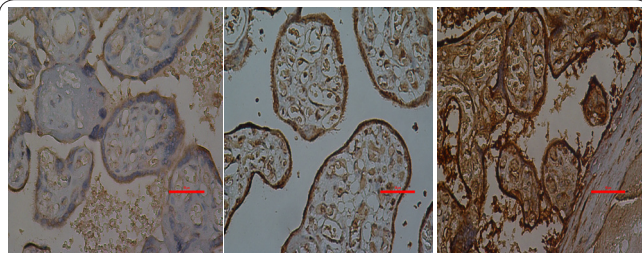


Figure 1. Immunohistochemical localization of Vascular Endothelial Growth Factor (VEGF) in the (a) control group, (b) mild preeclampsia group and (c) severe preeclampsia group. Red arrows, expression of VEGF in the placental villi (Scale bars, 50 μ m).

cental bed was supported by light microscopic findings. There was luminal narrowing of decidual artery and decidual lesions in placental tissue of preeclamptic groups. This situation was more prominent in severe preeclamptic group. In preeclamptic placentas, we observed a strong increase of VEGF (Figure 1) and Apelin (Figure 2), decreased Annexin A5 (Figure 3) expression levels. Specifically for Annexin A5, we found a strong immunopositivity in the cytoplasm of both cytotrophoblast and syncytiotrophoblast cells, together with a diffuse immunopositivity in the stroma of placental villi. Results of the immunohistochemical study, in a normal pregnant woman, mild and severe preeclamptic patients are shown in figures a, b and c, respectively.

Discussion

Macroscopic and microscopic alterations occur in placental structures in pregnancies with preeclampsia complications. It is evident that preeclampsia is a placental formation problem and a structural problem in placental bed especially in spiral arteries. We also observed macroscopic and microscopic alterations in placental bed alterations associated with pathophysiology of preeclampsia. In normal placentations the cytotrophoblast cells invade the uterine spiral arteries and transform them from small-sized resistance vessels into large-sized resistance vessels in order to provide adequate perfusion for both villous and fetal growth (4). In preeclampsia, this invasion is limited to the proximal decidua, and spiral arteries fail to dilate and remain responsive to vasomotor influences, which leads to high-resistance chorioplacental circulation (10,11). As a result, the average diameter of the blood vessels decreases and causes acceleration of placental ischemia (4). Given that defects in angiogenesis and remodeling of the trophoblast lead to maldevelopment, and inadequate placental mass, placental dysfunction, and chronic hypoxemia, endothelial dysfunctions play key role in the pathogenesis of preeclampsia, VEGF and pro-angiogenic proteins produced by villous syncytiotrophoblasts have been the focus of many studies (12,13,14, 15). Some of previous studies comparing placental expression of the VEGF system, which is known to be regulated response to mainly placental hypoxia, noted increased placental VEGF and immunostaining in preeclampsia pregnancies (12,13,16,17). Induction and upregulation of the VEGF system by chronic hypoxia and endothelial activation were suggested as possible mechanisms of this increase (4). In the present study, in

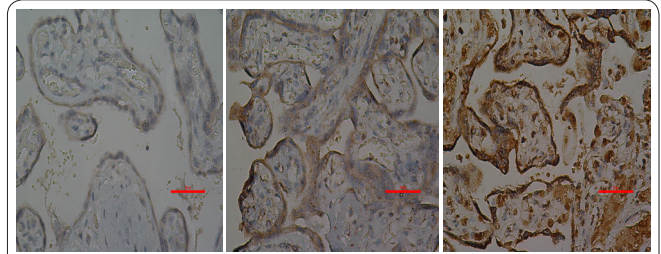


Figure 2. Immunohistochemical localization of Apelin (AP) in the (a) control group, (b) mild preeclampsia group and (c) severe preeclampsia group. Red arrows, expression of AP in the placental villi (Scale bars, 50 μ m).

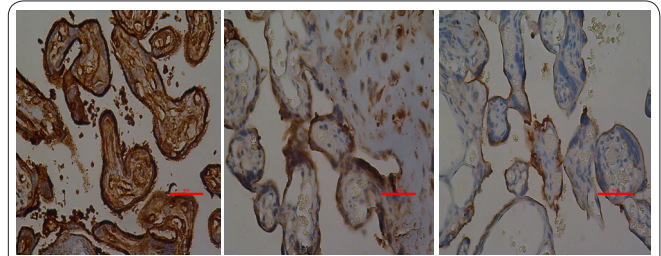


Figure 3. Immunohistochemical localization of Annexin A5 (ANXA5) in the (a) control group, (b) mild preeclampsia group and (c) severe preeclampsia group. Red arrows, expression of ANXA5 in the placental villi (Scale bars, 50 μ m).

proportion with intensity of disease VEGF was found to be significantly increased in placentas of preeclamptic patients when compared with mild preeclampsia and the controls. Pregnancy entails dramatic cardiovascular, body fluid and metabolic changes, both in humans and rodents. Heart rate and plasma volume increase with 40 % while blood pressure decreases progressively. In addition, gestational weight gain is accompanied by progressive adipocyte hypertrophy and insulin resistance (18). Apelin may well be involved in these adaptations, but few studies have examined its role in physiological or pathological pregnancies. Based on its potential actions, Apelin could be implicated in pathophysiology of preeclampsia (through the regulation of blood pressure and angiogenesis), in the regulation of fetal growth (through its effects on plasma volume expansion) and in the pathophysiology of gestational diabetes mellitus (through the regulation of glucose metabolism). To date, the peptide and its receptor have been localized in first- and third-trimester human placentas, and are markedly upregulated in preeclamptic pregnancies. There are studies presenting increased placental Apelin in the preeclamptic women (19). In our study increased Apelin immunoreactivity in preeclamptic placentas were determined which is also consistent with literature. Annexin A5 may serve a thrombomodulatory function in the placental circulation, where it appears necessary for the maintenance of placental integrity (20,21), infusion of polyclonal anti-Annexin A5 antibodies to pregnant mice with resulted in placental infarction and pregnancy wastage (20). The protein is expressed in apparently constitutive manner by human placental trophoblasts and has been immunolocalized to the apical surface of the syncytiotrophoblasts lining the placental villi where it is densely expressed (20). Recently, it was reported that Annexin A5 expression is decreased in trophoblasts of preeclamptic placentas and that the degree of decrease correlated with elevation of markers

for activation of blood coagulation (22). In our study we have found that immunoreactivity of Annexin A5 in preeclamptic patients was attenuated which supports diffuse arterial microthrombus progress in preeclamptic placental bed. In our study, consistent with literature, VEGF and Apelin were proportionally increased and Annexin A5 was decreased according to severity of the disease. As a result, it is concluded that VEGF which has well defined role in preeclampsia progress stages and Apelin and Annexin A5 which are multifunctional and their functions are at research stage may have roles in pathophysiology in disease after evaluation of normal and preeclamptic patients. According to our results we thought that Apelin and Annexin A5 may also have role in mechanisms which lead to formation of preeclampsia as VEGF. More studies are needed in order to explain pathophysiology of the disease and to clarify functions of those parameters. In addition biomarkers are needed for predicting preeclampsia at an early stage. We consider that predicting preeclampsia in early stage may be possible through such biomarkers in future studies.

Acknowledgments

We thank Okan Arihan for refining the language of the manuscript and Siddik Keskin for statistical analysis. This study was supported by funds from The Scientific Research Council of Van Yuzuncu Yil University (YYU, BAPK, Project no:2015-TF-B132).

Declaration of interest

Our manuscript is an original work, neither published so far nor communicated elsewhere for publication. The authors report no conflicts of interest. The authors alone are responsible for the content and writing of this article.

References

1. American College of Obstetricians and Gynecologists; Task Force on Hypertension in Pregnancy. Hypertension in pregnancy. Report of the American College of Obstetricians and Gynecologists' Task Force on Hypertension in Pregnancy. *Obstet Gynecol* 2013; 122: 1122-31.
2. Saha T, Halder M, Das A and Das SK. Role of nitric oxide, angiogenic growth factors and biochemical analysis in preeclampsia. *Indian J Biochem Biophys* 2013; 50: 462-66.
3. Gourvas V, Soulitzis N, Konstantinidou A, Dalpa E, Koukoura Q, Koutroulakis D, et al. Reduced ANXA5 mRNA and protein expression in pregnancies complicated by preeclampsia. *Thromb Res* 2014; 133: 495-500.
4. Kurtoğlu E, Altunkaynak BZ, Aydın I, Ozdemir AZ, Altun G, Kocuk A, et al. Role of vascular endothelial growth factor and placental growth factor expression on placenta structure in preeclamptic pregnancy. *J. Obstet. Gynaecol Res* 2015; 41: 1533-41.
5. Galazios G, Papazoglou D, Tsikouras P & Kolios G. Review. Vascular endothelial growth factor gene polymorphisms and pregnancy. *The Journal of Maternal-Fetal & Neonatal Med* 2009; 22: 371-78.
6. Van Mieghem T, Van Bree R, Van Herck E, Pijnenborg R, Deprest J, Verhaeghe J. Maternal Apelin Physiology during Rat pregnancy: The Role of the Placenta. *Placenta* 2010; 31: 725-30.
7. Wang G, Kundu R, Han S, Qi X, Englander EW, Quertermous T, Greely JR GH. Ontogeny of Apelin And Its Receptor In The Rodent Gastrointestinal Tract. *Regul Pept.* 2009; 158: 32-9.
8. Sifakis S, Soufla G, Koukoura O, Soulitzis N, Koutroulakis D, Maiz N, et al. Decreased Annexin A5 mRNA placental expression in pregnancies complicated by fetal growth restriction. *Thrombosis Research* 2010; 125: 326-31.
9. Mutlu C, Koyutürk M, Karpuz V. Evaluation of endothelial nitric oxide synthase (eNOS) immunoreactivity of fetal and maternal placenta. *Cerrahpaşa J Med* 2005; 36: 109-15.
10. Saeed I, Iqbal I, Sarfaraz R, Qamar K, Butt SA, Shaukat S. Histomorphological changes in placentae of preeclamptic mothers with reference to vasculosyncytial membrane thickness and syncytial knot formation. *J of Rawalpindi Med College (JRMC)* 2012; 16: 51-4.
11. Pijnenborg R, Vercruyse L, Hanssens M. The uterine spiral arteries in human pregnancy: facts and controversies. *Placenta* 2006; 27: 939-58.
12. Dubova EA, Pavlov KA, Lyapin VM, Shchyogolev AI and Sukhikh GT. Vascular endothelial growth factor and its receptors in the placental villi of pregnant patients with pre-eclampsia. *Bull Exp Biol Med* 2013; 154: 792-95.
13. Akercan F, Cirpan T, Terek MC, Ozcakar HT, Giray G, Sagol S, et al.. The immunohistochemical evaluation of VEGF in placenta biopsies of pregnancies complicated by preeclampsia. *Arch Gynecol Obstet* 2008; 277: 109-14.
14. Sezer SD, Kucuk M, Doger FK, Yuksel H, Odabası AR, Turkmen MK, et al. VEGF, PlGF and HIF-1 α in placentals of early-and late-onset pre-eclamptic patients. *Gynecol Endocrinol* 2013; 29: 797-800.
15. Ferrara N, Keyt B. Vascular endothelial growth factor: Basic biology and clinical implications (EXS, 79) (the series *Experientia Supplementum*) 1997; 209-232.
16. Simmons LA, Hennessy A, Gillin AG, Jeremy RW. Uteroplacental blood flow and placental vascular endothelial growth factor in normotensive and pre-eclamptic pregnancy. *BJOG* 2000; 107: 678-85.
17. Trollmann R, Amann K, Schoof E, Beinder E, Wenzel D, Rascher W, et al. Hypoxia activates the human placental vascular endothelial growth factor system in vitro and in vivo: Up-regulation of vascular endothelial growth factor in clinically relevant hypoxic ischemia in birth asphyxia. *Am J Obstet Gynecol* 2003; 188: 517-23.
18. Van Mieghem T, Van Bree R, Van Herck E, Deprest J, Verhaeghe J. Insulin-like growth factor-II regulates maternal hemodynamic adaptation to pregnancy in rats. *Am J Physiol Regul Integr Comp Physiol* 2009; 297: 1615-21.
19. Cobellis L, De Falco M, Mastrogiacomo A, Giraldo D, Dattilo D, Scaffa C, et al. Modulation of apelin and APJ receptor in normal and preeclampsia-complicated placentas. *Histol Histopathol* 2007; 22: 1-8.
20. Rand JH. Review. The annexinopathies: a new category of diseases. *Biochimica et Biophysica Acta.(BBA)-Molecular Cell Research* 2000; 1498: 169-173.
21. Ornaghi S, Vergani S, Urban G, Giardini V, Moltrasio F, Leone BE. Immunohistochemical expression of Annexin A5 in preeclamptic placentas. *Placenta* 2011; 32: 264-68.
22. Shu F, Sugimura M, Kanayama N, Kobayashi H, Kobayashi T, Terao T. Immunohistochemical study of Annexin V Expression in Placentae of Preeclampsia. *Gynecol Obstet Invest* 2000; 49: 17-23.