

Diabetes up-regulated collagen IV and laminin $\alpha 5$ genes in mRNA and protein levels in seminiferous tubules of C57BL/6 adult mice

Elnaz Khordad¹, Mohammad Reza Nikravesh^{1*}, Mehdi Jalali¹, Ali Reza Fazel¹, Mojtaba Sankian², Fatemeh Alipour¹¹ Department of Anatomy and Cell Biology, Faculty of Medicine, Mashhad University of Medical Sciences, Mashhad, Iran² Bou-Ali Research Institute, Immunology Research Center, Mashhad University of Medical Sciences, Mashhad, Iran

*Correspondence to: Nikraveshmr@mums.ac.ir

Received December 5, 2019; Accepted June 20, 2020; Published July 31, 2020

Doi: <http://dx.doi.org/10.14715/cmb/2020.66.5.28>

Copyright: © 2020 by the C.M.B. Association. All rights reserved.

Abstract: Diabetes is a disease associated with impairment of the male reproductive system that causes complications such as decreased testosterone, the diameter of the seminiferous tubule, libido, and fertility. Extracellular matrix (ECM) molecules are involved in testicular development and spermatogenesis. Laminin and collagen are key proteins in seminiferous tubule basement membrane and play an important role in spermatogenesis. The present study was conducted to investigate the effect of diabetes on collagen IV and laminin $\alpha 5$ changes in mice testis. In this experimental study, 40 mice (C57BL/6) were divided randomly into 4 groups: 1) Control group: without intervention, 2) Diabetic group: treated mice with 50 mg/kg streptozotocin (STZ), 3) Diabetic + Insulin group: treated mice with STZ and insulin, and 4) Sham group: received citrate buffer. After 35 days, the left testes of all specimens were used for Real-Time PCR while their right testes were applied for immunohistochemical study and Periodic acid-Schiff (PAS) staining. This study showed that gene expression and immunoreactivity of laminin $\alpha 5$ and collagen IV were significantly increased in diabetic mice compared to other groups ($P < 0.05$). Also, PAS staining showed the thickness of seminiferous tubule basement membrane in the Diabetic group compared to other group increased significantly ($p < 0.05$). In Diabetic + Insulin compared to Diabetic group, gene expression, the intensity of immunoreactivity and thickness of seminiferous tubule basement membrane decreased significantly ($P < 0.05$). Our findings indicated that diabetes causes up-regulation of collagen IV and laminin $\alpha 5$ in mRNA and protein levels in the seminiferous tubule basement membrane and may cause disorder in spermatogenesis in mice.

Key words: Diabetes; Testis; Basement membrane; Laminin $\alpha 5$; Collagen IV.

Introduction

Infertility is considered as one of the serious social problems among nations. In this regard, a male factor is generally involved in half of the infertility problems (1). Several risk factors can influence the male infertility problem, including some diseases such as diabetes. Diabetes mellitus is one of the most common metabolic diseases that are associated with hyperglycemia. Failure to produce insulin causes type I diabetes, peripheral tissue resistant to insulin, and also decreased insulin secretion from pancreatic beta cells generates type II diabetes (2, 3). Long-term diabetes has adverse effects on the visual system, kidney, the cardiovascular, and nervous system (4).

Studies showed that chronic hyperglycemia increases generation of free radicals, particularly reactive oxygen species (ROS), for all tissues (5-8). The studies have shown that diabetes has a variety of functional and structural effects on the male reproductive system and spermatogenesis (9). Several studies have shown that diabetes causes complications like decreased testosterone level, decreased the diameter of seminiferous tubule and libido, increased sperm abnormalities, and infertility (10, 11). Researchers have shown that diabetes may cause changes in the structure of the extracellular matrix (ECM) (12). It has been shown that ECM

molecules are involved in the process of development of the testes and spermatogenesis. ECM is a network of proteins and glycoproteins that provides physical support for cells and tissues and plays a role in regulating cell behavior, differentiation and migration. The major ECM components include laminin, fibronectin, collagen I, IV, and VI, versican, and decorin (13-15). Changes in the composition and structure of ECM may alter cell function in different ways. At the molecular level, these changes may be associated with alteration in the metabolism of different types of collagen, fibronectin, and laminin (16). The basement membrane is a part of the extracellular matrix that underlies the seminiferous tubules. This membrane was prepared using Sertoli cells and Myoid cells (17-22). It has been shown that at approximately the second week of pregnancy laminin and collagen IV and heparan sulfate are involved in organizing the undifferentiated testicular cords and fibronectin presents at this location even earlier than this time (12). Collagen IV is a non-fibrillar collagen that is the most abundant protein in the basement membrane and creates about 50% of the basement membrane. Biosynthesis of collagen IV has a complex process encompassing numerous specific and non-specific enzymes. Laminin is the most abundant non-collagenous proteins and plays a role in cell differentiation, cell migration, and cellular junctions. Laminin is composed of three Alpha, Beta,

and Gamma chains. These chains can connect to each other to form at least 15 different isoforms of laminin. Laminins have important functions such as contributing information of basement membrane and act as ligands for receptors on cells (23, 24). As collagen and laminin are two major components of ECM that involve in forming the undifferentiated testicular cords and cell behavior, moreover ECM molecules are involved in the process of development of the testes and spermatogenesis and considering the increasing prevalence of diabetes and its effects on spermatogenesis as well as the importance of the matrix in male infertility, we investigated the effects of diabetes on collagen IV and laminin $\alpha 5$ expression in mice testes.

Materials and Methods

Animals

For this experimental study, 40 male *C57BL/6* mice aging 2 months with 20-25 g body weight were purchased from Pasteur Institute, Tehran, Iran. The study was done in accordance with the instructions of the National Institute of Health Guide for the Care and Use of Laboratory Animals (NIH Publications No. 80-23, revised 1978) and approved by Ethical Committee at Mashhad University of Medical Sciences, Mashhad, Iran. The mice were housed in standard animal cages and kept under standard laboratory conditions (12h light and dark cycle, at 21°C temperature, and 50% relative humidity). Animals had free access to mice pelleted chow and drinking water during the experimental period.

Study design

The mice were randomly divided into 4 groups. Each group included 10 animals: 1) Control group: without any intervention, 2) Diabetic group: treated mice with Streptozotocin (STZ), 3) Diabetic + Insulin group: treated mice with STZ and insulin (1.5 U of LANSULIN 70/30), and 4) Sham group: that received citrate buffer. Diabetes in mice was induced by intraperitoneal injection of STZ (Sigma company, USA) at a dose of 50 mg/kg in citrate buffer (freshly dissolved in 0.01 mol/L (pH: 4.5) sodium citrate buffer) for 5 consecutive days (25). Next, 72 h after the last injection, diabetes was confirmed by measuring blood glucose levels of the tail vein with a glucometer (Easy Gluco, Infopia, Korea). Mice with blood glucose levels of 250 mg/dL or higher were considered diabetic. At the end of the experimental period after 35 days (spermatogenesis duration in mice) (26), animals were anesthetized and sacrificed

by cervical dislocation and testes were removed from each group. The left testes were stored at -70°C for RNA extraction and the right testes were washed in normal saline and fixed in 10% formalin for immunohistochemical study and Periodic acid-Schiff (PAS) staining.

RNA extraction

Total RNA was isolated from testicular tissue by using Total RNA Extraction Kit (Parstous Company, Iran) in accordance with the instruction of the manufacturer. Briefly, the tissue was homogenized in 750 μ l of RL solution and then 150 μ l chloroform was added to the solution. Afterward, it was incubated at room temperature for 3 min and centrifuged for 12 min, at 13000 rpm. In the next step, 400 μ l of the upper phase was transferred into a tube and an equal volume of 70% ethanol was added to the solution. The tube was centrifuged for 1 min at 4°C and 13000 rpm. Then 700 μ l and after that 500 μ l PW was added respectively and centrifuged for 2 min at 4°C at 13000 rpm and finally, 50 μ l Diethyl pyrocarbonate (DEPC) was added and centrifuged for 1 min at 4°C and at 13000 rpm. The purity and integrity of obtained total RNA were checked by 260/280 nm ratio measurement and 1% agarose gel electrophoresis, respectively. Total RNA was kept at -70°C.

cDNA synthesis

Reverse transcription (RT) reagents were purchased and cDNA was synthesized by using cDNA synthesis Kit (Parstous, Company, Iran) according to the manufacturer's instruction. The total RNA (0.5 μ l) was reverse transcribed with 1 μ l oligo (dt) and 8.5 μ l DEPC water. The solution was incubated at 65°C for 5 min. Next, it was immediately transferred to ice and then added 10 μ l reverse transcriptions (RT) premix (reaction volume =20 μ l). The samples were incubated at 50°C for 60 min and then the transcriptase was inactivated at 70°C for 10 min. cDNA samples were stored at -70°C.

Real-time PCR

To assess gene expression, real-time PCR was performed by using the Applied Biosystems Real-Time PCR Instruments (ABI) and SYBER Green/ROX master mix (Parstous Corporation, Iran) kit). To determine gene expression of *laminin $\alpha 5$* and *collagen IV*, real-time PCR method was conducted. All samples were tested in duplicate. The primer sequences are described in Table 1. PCR master mix contains 10 μ l SYBR Green, 1 μ l of each gene-specific primer (forward and reverse), 7.1 μ l of distilled water, 0.4 μ l ROX, and 0.5 μ l of cDNA (volume of reaction = 20 μ l in each tube). The PCR pro-

Table 1. Sequences of primers used for real-time PCR.

Gene	primer sequences	product size (bp)	Annealing temperature (°C)
<i>Collagen IV</i>	5'-AAGCTGTAAGCATTCGCGTAGTA-3' (R) 5'- ATTCCTTTGTGATGCACACCAG-3' (F)	107	58
<i>Laminin $\alpha 5$</i>	5'-TACCAACGAAGGGCTGCG- 3'(R) 5'-CGTCCCACAGGAATAGGCT- 3' (F)	109	58
<i>GAPDH</i>	5'- CTGTAGCCATATTCATTGTCATACCA-3' (R) 5'-AACTCCCATTCTTCCACCTTTG-3' (F)	385	58

GAPDH; Glyceraldehyde 3-phosphate dehydrogenase.

Diabetic group ($P < 0.001$). There was no considerable difference between Sham and Control groups (Figure 2).

Immunoreactivity of laminin $\alpha 5$ and collagen IV in mice testis

This study was conducted to evaluate the intensity of laminin $\alpha 5$ and collagen IV proteins in seminiferous tubule basement membrane according to the intensity of color darkness. Our findings showed that the intensity of laminin $\alpha 5$ immunoreactivity in the Diabetic group increased significantly compared to the Control and Sham groups ($P < 0.001$). As presented in Figure. 3, a significant decrease occurred in Diabetic + Insulin compare to Diabetic groups ($P < 0.001$). The results of this study indicated that collagen IV immunoreactivity was similar to laminin $\alpha 5$ immunoreactivity. A considerable increase was also observed in a Diabetic group, compared to the Control and Sham groups ($P < 0.001$). We also found a significant decrease in Diabetic + Insulin group compared to Diabetic group ($P < 0.001$). No remarkable difference was noticed between Sham and Control groups in the intensity of laminin $\alpha 5$ and collagen IV (Figure. 4).

Results of PAS staining in basement membrane of mice seminiferous tubules

Our findings showed that the thicknesses of semi-

niferous tubule basement membrane in the Diabetic group compared to the Control and Sham groups were increased significantly ($p < 0.05$). Also, a significant increase was observed ($p < 0.05$) in the Diabetic group compared to Diabetic + Insulin group. There was no significant difference among Control, Sham, and Diabetic + Insulin groups (Figure. 5).

Discussion

This study was designed to evaluate the effects of diabetes on laminin $\alpha 5$ and collagen IV genes in mRNA and protein levels in seminiferous tubules of adult mice. The results of this study revealed a statistically significant difference between diabetic and other groups in laminin $\alpha 5$ and collagen IV genes expression and immunoreactivity. Studies showed that in diabetic patients the level of oxidative stress was high due to excess generation of ROS and reduction in efficiency of antioxidant enzyme defenses. Oxidative stress is an important factor in the impairment of male fertility (5). Previous studies have shown that the ECM of most tissues is not well preserved against oxidative stress. Moreover, it has been shown that diabetes may cause changes in the structure of the ECM and the oxidative stress induced by diabetes can cause a change in the gene expression (36). A previous showed that the ECM molecules are

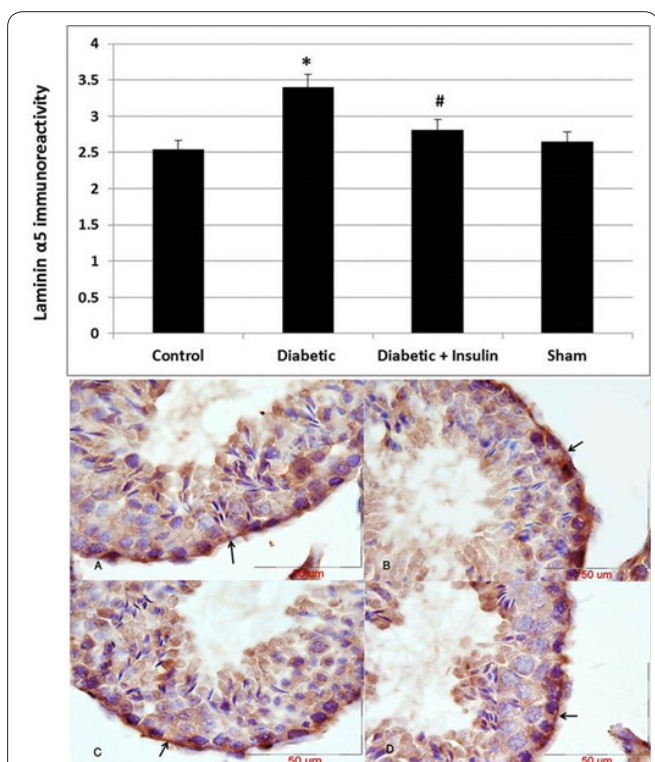


Figure 3. The graph shows the effect of diabetes on immunoreaction of laminin $\alpha 5$ protein in the basement membrane of the seminiferous tubule. There was a significant increase in Diabetic group compare with Control and Sham groups $*P < 0.05$ and a significant decrease in Diabetic + Insulin group compare to Diabetic group $\#P < 0.05$. The photomicrograph shows the effect of diabetes on immunoreactivity of laminin $\alpha 5$ protein in the basement membrane of the seminiferous tubule; Photomicrographs show immunoreactivity of laminin $\alpha 5$ protein in Control (A), Diabetic (B), Diabetic + Insulin (C), and Sham (D) groups; Positive immunoreactions show a different grade of intensity brown color (Arrows); Scale bar = 50 μm .

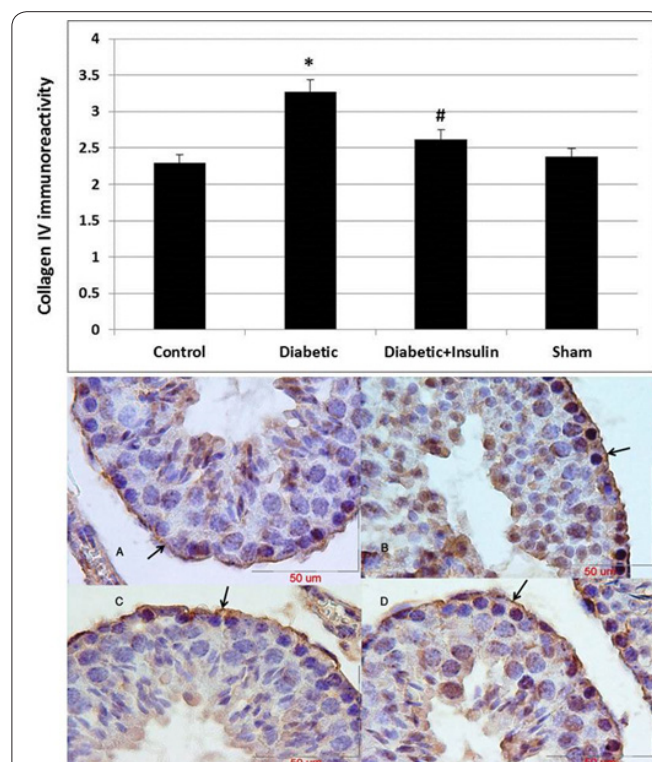


Figure 4. The graph shows the effect of diabetes on immunoreaction of collagen IV protein in the basement membrane of the seminiferous tubule. There was a significant increase in Diabetic group compare with Control and Sham groups $*P < 0.05$ and a significant decrease in Diabetic + Insulin group compare to Diabetic group $\#P < 0.05$. The photomicrograph shows the effect of diabetes on immunoreactivity of collagen IV protein in the basement membrane of the seminiferous tubule; Photomicrographs show immunoreactivity of collagen IV protein in Control (A), Diabetic (B), Diabetic + Insulin (C), and Sham (D) groups; Positive immunoreactions show a different grade of intensity brown color (Arrows); Scale bar = 50 μm .

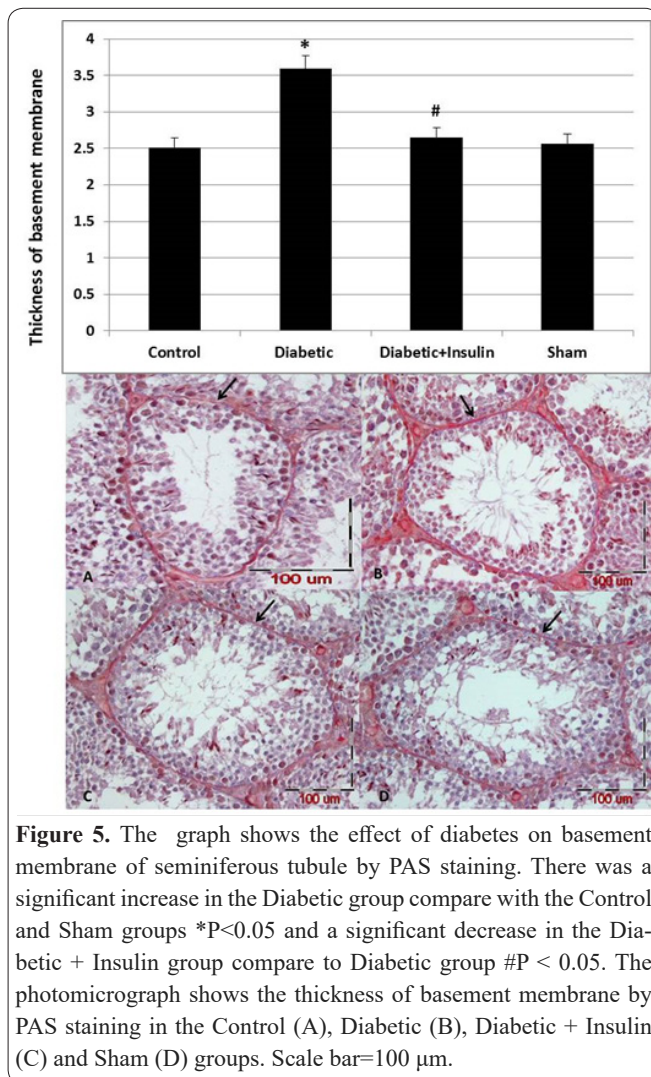


Figure 5. The graph shows the effect of diabetes on basement membrane of seminiferous tubule by PAS staining. There was a significant increase in the Diabetic group compare with the Control and Sham groups * $P < 0.05$ and a significant decrease in the Diabetic + Insulin group compare to Diabetic group # $P < 0.05$. The photomicrograph shows the thickness of basement membrane by PAS staining in the Control (A), Diabetic (B), Diabetic + Insulin (C) and Sham (D) groups. Scale bar=100 μm .

involved in the development of the testes and spermatogenesis. Among various components of the basement membrane, collagen IV, laminin, and heparan sulfate proteoglycan have been shown to involve in Germ cell and Sertoli function (12, 17, 19, 37, 38). In some spermatogenesis disorders cases, the lamina propria of seminiferous tubule become thick by an increase in the ECM components with differentiation of Myoid cells to fibroblastic nature, fibrosis in peritubular cells, and interstitium with sporadic Leydig cells, as well as edema in interstitium that prevents normal development of germ cells and subsequently male fertility (19, 39, 40). Previous studies have shown that diabetes causes both degeneration and inflammation in the rat's testes (41) and also causes a reduction in seminiferous tubule diameter, increased thickening of the seminiferous tubule basement membrane, and degenerated germ cells in diabetic rats (3). Our results based on immunohistochemical and real-time PCR techniques showed that laminin $\alpha 5$ and collagen IV immunoreactivity and mRNA expression in the Diabetic group was slightly higher compared to the Control group. Also, PAS staining showed that thickness of seminiferous tubule basement membrane was increased significantly in the Diabetic group compared to other groups. Davis *et al.* conducted a study on differential expression in the Sertoli cells extracellular matrix. Using immunofluorescence they revealed that the highest expression of laminin and fibronectin occurred during the period of evolution (1-10 days) and then

maintained at a low level while the expression of collagen IV reaches its peak at a later stage (17). The present study demonstrated effects of diabetes on changes in the amount of collagen IV and laminin $\alpha 5$, through evaluating the samples by immunohistochemistry and real-time PCR techniques. Laminin $\alpha 5$ and collagen IV level in the Diabetic group increased while in the Diabetic + Insulin group both laminin $\alpha 5$ and collagen IV levels was statistically significant decrease. In another study, it was demonstrated that diabetes affects the kidney extracellular matrix, they found that the amount of collagen IV decreased while the amount of laminin $\alpha 5$ increased (42). Similarly, the results of our study showed an increase in the laminin $\alpha 5$ rate in the Diabetic group; however, unlike their findings in our study, the amount of collagen IV also increased. In addition, our study showed that in the group that received insulin, both the collagen and laminin $\alpha 5$ were significantly reduced compared to the Diabetic group. Moreover, in the Diabetic + Insulin group compared to the Diabetic group, the thickness of seminiferous tubule basement membrane by using PAS staining was reduced significantly. Because the ECM of most tissues is not well preserved against oxidative stress, an increase occurred in the sensitivity of tissues to proteolytic cleavage and ECM permeability, leading to the altered function of the organ (38, 43). Previous studies have shown that diabetes increases oxidative stress in the testis and hyperglycemia decreases the antioxidant defenses system and reactive oxygen species overproduction (5, 6, 41, 44, 45). Moreover, it has been reported that the ECM of most tissues is not well preserved against oxidative stress (38). As that in previous studies, an increase in oxidative stress associated with diabetes was observed. Moreover, it was observed that oxidative stress could lead to some changes in the expression of the gene in the testis tissue. Therefore, oxidative stress is likely to be an effective factor in our study. However, further investigation clearly is warranted.

The results of this study indicated that diabetes causes spermatogenesis disorder in adult mice via up-regulation of Collagen IV and Laminin $\alpha 5$ genes in mRNA and protein levels in the seminiferous tubule basement membrane.

Acknowledgements

The data used in this paper is from a Ph.D. student thesis (NO: 931750). This study was supported financially by Vice Chancellor for Research at Mashhad University of Medical Sciences, Mashhad, Iran. The authors would like to thank Mrs. F. Motejadded and F.Tajik for her excellent technical assistances.

Conflict of interest

The authors confirm that there is no conflict of interest regarding the publication of this article

Author's contributions

Elnaz Khordad, Mohammad Reza Nikravesh, Mehdi Jalali, Alireza Fazel, Mojtaba Sankian, Fatemeh Ali-pour. Kh.E.; performed experiments, analysed data, Performed transporter experiments, co-wrote the paper, Provided essential mouse strains, N.Mr.; Supervised the

search, co-wrote the paper, Designed experiments, J.M.; Supervised the research, co-wrote the paper, Designed experiments, F.A.R.; Consultant, S.M.; Consultant, A.F.; performed experiments, co-wrote the paper.

References

- Amini M, Shirinbayan P, Behnam B et al. Correlation between expression of CatSper family and sperm profiles in the adult mouse testis following Iranian Kerack abuse. *Andrology*. May 2014; 2(3): 386-393.
- Gispén WH, Biessels GJ. Cognition and synaptic plasticity in diabetes mellitus. *Trends Neurosci*. Nov 2000; 23(11): 542-549.
- Guneli E, Tugyan K, Ozturk H, Gumustekin M, Cilaker S, Uysal N. Effect of melatonin on testicular damage in streptozotocin-induced diabetic rats. *Eur Surg Res*. 2008; 40(4): 354-360.
- Sasso FC, De Nicola L, Carbonara O et al. Cardiovascular risk factors and disease management in type 2 diabetic patients with diabetic nephropathy. *Diabetes Care*. Mar 2006; 29(3): 498-503.
- Pourentezari M, Talebi AR, Mangoli E, Anvari M, Rahimpour M. Additional deleterious effects of alcohol consumption on sperm parameters and DNA integrity in diabetic mice. *Andrologia*. Jun 2016; 48(5): 564-569.
- Abd El-Twab SM, Mohamed HM, Mahmoud AM. Taurine and pioglitazone attenuate diabetes-induced testicular damage by abrogation of oxidative stress and up-regulation of the pituitary-gonadal axis. *Canadian journal of physiology and pharmacology*. Jun 2016; 94(6): 651-661.
- Iqbal S, Khan S, Naseem I. Antioxidant Role of Vitamin D in mice with Alloxan-Induced Diabetes. *Canadian journal of diabetes*. Dec 4 2017.
- Mahesh T, Menon VP. Quercetin alleviates oxidative stress in streptozotocin-induced diabetic rats. *Phytotherapy research : PTR*. Feb 2004; 18(2): 123-127.
- Ballester J, Munoz MC, Dominguez J, Rigau T, Guinovart JJ, Rodriguez-Gil JE. Insulin-dependent diabetes affects testicular function by FSH- and LH-linked mechanisms. *Journal of andrology*. Sep-Oct 2004; 25(5): 706-719.
- Abdolahnejad A, Gol A, Sh D. Garlic effects on reproductive complications of diabetes mellitus in male rats. *Physio & Pharma*. 2009; 12: 297-207.
- Salimnejad R, Sazegar G, Saedi Borujeni MJ, Mousavi SM, Salehi F, Ghorbani F. Protective effect of hydroalcoholic extract of *Teucrium polium* on diabetes-induced testicular damage and serum testosterone concentration. *International journal of reproductive biomedicine (Yazd, Iran)*. Apr 2017; 15(4): 195-202.
- Raychoudhury S, Raychoudhury K, Cl. M. Biotechnological evaluation of extracellular matrix proteins expressed by cultured testicular cells. *Biotech*. 2011; 3: 62-71.
- Luo ZJ, King RH, Lewin J, Thomas PK. Effects of nonenzymatic glycosylation of extracellular matrix components on cell survival and sensory neurite extension in cell culture. *J Neurol*. Apr 2002; 249(4): 424-431.
- Oshitari T, Polewski P, Chadda M, Li AF, Sato T, Roy S. Effect of combined antisense oligonucleotides against high-glucose- and diabetes-induced overexpression of extracellular matrix components and increased vascular permeability. *Diabetes*. Jan 2006; 55(1): 86-92.
- Soucy PA, Romer LH. Endothelial cell adhesion, signaling, and morphogenesis in fibroblast-derived matrix. *Matrix Biol*. Jun 2009; 28(5): 273-283.
- Yasuda H, Terada M, Maeda K et al. Diabetic neuropathy and nerve regeneration. *Prog Neurobiol*. Mar 2003; 69(4): 229-285.
- Davis CM, Papadopoulos V, Sommers CL, Kleinman HK, Dym M. Differential expression of extracellular matrix components in rat Sertoli cells. *Biology of reproduction*. Nov 1990; 43(5): 860-869.
- Gesing A, Lewinski A, Karbownik-Lewinska M. The thyroid gland and the process of aging; what is new? *Thyroid research*. Nov 24 2012; 5(1): 16.
- Gulkesen KH, Erdogru T, Sargin CF, Karpuzoglu G. Expression of extracellular matrix proteins and vimentin in testes of azoospermic man: an immunohistochemical and morphometric study. *Asian journal of andrology*. Mar 2002; 4(1): 55-60.
- Loveland K, Schlatt S, Sasaki T, Chu ML, Timpl R, Dziadek M. Developmental changes in the basement membrane of the normal and hypothyroid postnatal rat testis: segmental localization of fibulin-2 and fibronectin. *Biology of reproduction*. May 1998; 58(5): 1123-1130.
- Ulisse S, Rucci N, Piersanti D et al. Regulation by thyroid hormone of the expression of basement membrane components in rat prepubertal Sertoli cells. *Endocrinology*. Feb 1998; 139(2): 741-747.
- Yazama F, Esaki M, Sawada H. Immunocytochemistry of extracellular matrix components in the rat seminiferous tubule: electron microscopic localization with improved methodology. *The Anatomical record*. May 1997; 248(1): 51-62.
- Khoshnoodi J, Pedchenko V, Hudson BG. Mammalian collagen IV. *Microsc Res Tech*. May 2008; 71(5): 357-370.
- Patton BL. Laminins of the neuromuscular system. *Microsc Res Tech*. Nov 1 2000; 51(3): 247-261.
- Thomas J, Garg ML, Smith DW. Dietary resveratrol supplementation normalizes gene expression in the hippocampus of streptozotocin-induced diabetic C57Bl/6 mice. *J Nutr Biochem*. Mar 2014; 25(3): 313-318.
- Ray D, Pitts PB, Hogarth CA, Whitmore LS, Griswold MD, Ye P. Computer simulations of the mouse spermatogenic cycle. *Biology open*. Dec 12 2014; 4(1): 1-12.
- Jaramillo ML, Pereira AG, Davico CE et al. Evaluation of reference genes for reverse transcription-quantitative PCR assays in organs of zebrafish exposed to glyphosate-based herbicide, Roundup. *Animal : an international journal of animal bioscience*. Nov 27 2017: 1-11.
- Pahang H, Nikravesh MR, Jalali M, Ebrahimzadeh Bideskan A, Zargari P, Sadr Nabavi A. Fibronectin regulation by vitamin C treatment in kidneys of nicotinic mice offspring. *Iranian Red Crescent medical journal*. Jul 2014; 16(7): e17056.
- Park EH, Kim DR, Kim HY, Park SK, Chang MS. Panax ginseng induces the expression of CatSper genes and sperm hyperactivation. *Asian journal of andrology*. Nov-Dec 2014; 16(6): 845-851.
- Aldaghi M, Sankian M, Sameni H, Safari M. Effects of Alpha Lipoic Acid Treatment on Laminin Alteration of the Sciatic Nerve in Streptozotocin Induced Diabetic Rats. *Middle East J Rehabil Health*. 2014; 2.
- Mohammadi S, Jalali M, Nikravesh MR et al. Effects of Vitamin-E treatment on CatSper genes expression and sperm quality in the testis of the aging mouse. *Iranian journal of reproductive medicine*. Dec 2013; 11(12): 989-998.
- Pfaffl MW. A new mathematical model for relative quantification in real-time RT-PCR. *Nucleic acids research*. May 1 2001; 29(9): e45.
- Tahajjodi SS, Amerion M, Mahdavi Shahri N, Jalali M, Nikravesh MR. The effect of maternal nicotine on basement membrane collagen IV of brain microvessels changes in neonatal Balb/C mice. *Iranian journal of reproductive medicine*. Apr 2014; 12(4): 275-280.
- Pujar A, Pereira T, Tamgadge A, Bhalerao S, Tamgadge S. Comparing The Efficacy of Hematoxylin and Eosin, Periodic Acid Schiff and Fluorescent Periodic Acid Schiff-Acridine Techniques

for Demonstration of Basement Membrane in Oral Lichen Planus: A Histochemical Study. *Indian Journal of Dermatology*. Sep-Oct 2015; 60(5): 450-456.

35. Banaei S, Ahmadiasl N, Alihemmati A. Comparison of the Protective Effects of Erythropoietin and Melatonin on Renal Ischemia-Reperfusion Injury. *Trauma monthly*. Jul 2016; 21(3): e23005.

36. Dkhil MA, Zrieq R, Al-Quraishy S, Abdel Moneim AE. Selenium Nanoparticles Attenuate Oxidative Stress and Testicular Damage in Streptozotocin-Induced Diabetic Rats. *Molecules (Basel, Switzerland)*. Nov 19 2016; 21(11).

37. Hadley MA, Byers SW, Suarez-Quian CA, Kleinman HK, Dym M. Extracellular matrix regulates Sertoli cell differentiation, testicular cord formation, and germ cell development in vitro. *The Journal of cell biology*. Oct 1985; 101(4): 1511-1522.

38. Sahoo DK, Roy A, Bhanja S, Chainy GB. Hypothyroidism impairs antioxidant defence system and testicular physiology during development and maturation. *General and comparative endocrinology*. Mar 01 2008; 156(1): 63-70.

39. Buzzard JJ, Morrison JR, O'Bryan MK, Song Q, Wreford NG. Developmental expression of thyroid hormone receptors in the rat testis. *Biology of reproduction*. Mar 2000; 62(3): 664-669.

40. Wajner SM, Wagner MS, Maia AL. Clinical implications of altered thyroid status in male testicular function. *Arquivos brasileiros de endocrinologia e metabologia*. Nov 2009; 53(8): 976-982.

41. Kanter M, Aktas C, Erbogaa M. Protective effects of quercetin against apoptosis and oxidative stress in streptozotocin-induced diabetic rat testis. *Food Chem Toxicol*. Mar 2012; 50(3-4): 719-725.

42. Poulosom R, Kurkinen M, Prockop DJ, Boot-Handford RP. Increased steady-state levels of laminin B1 mRNA in kidneys of long-term streptozotocin-diabetic rats. No effect of an aldose reductase inhibitor. *J Biol Chem*. Jul 25 1988; 263(21): 10072-10076.

43. Singh R, Hamada AJ, A A. Thyroid Hormones in Male Reproduction and Fertility. . *The Open Reproductive Science Journal*. 2011; 3: 98-104.

44. Agbaje IM, Rogers DA, McVicar CM et al. Insulin dependant diabetes mellitus: implications for male reproductive function. *Human reproduction (Oxford, England)*. Jul 2007; 22(7): 1871-1877.

45. Alves MG, Martins AD, Rato L, Moreira PI, Socorro S, Oliveira PF. Molecular mechanisms beyond glucose transport in diabetes-related male infertility. *Biochim Biophys Acta*. May 2013; 1832(5): 626-635.