

Original Research

Anti-inflammatory and wound healing effects of an essential oils-based bioadhesive gel after oral mucosa biopsies: preliminary results

Federico Scotti¹, Sem Decani², Andrea Sardella^{1,2}, Marcello Iriti³, Elena Maria Varoni^{1,2*#}, Giovanni Lodi^{1,2#}

¹ Dipartimento di Scienze Biomediche, Chirurgiche ed Odontoiatriche, Università degli Studi di Milano, Milan, Italy

² ASST Santi Paolo e Carlo, Presidio Ospedaliero San Paolo, Via Beldiletto 1/3 20142, Milan, Italy

³ Dipartimento di Scienze Agrarie e Ambientali, Università degli Studi di Milano, Milan, Italy

Correspondence to: elena.varoni@unimi.it

co-last authorship

Received December 28, 2017; Accepted May 4, 2018; Published June 25, 2018

Doi: <http://dx.doi.org/10.14715/cmb/2018.64.8.12>

Copyright: © 2018 by the C.M.B. Association. All rights reserved.

Abstract: Post-operative management of patients receiving oral biopsy includes the control of edema, pain, infection, and re-epithelization at the surgical site. This clinical study investigates the topical use of a bioadhesive gel, containing essential oils, to promote wound healing and prevent post-operative pain and infection, avoiding the need for surgical suture and chlorhexidine applications. Ten patients, who needed to receive oral biopsies (≤ 6 mm in diameter) for the diagnosis of mucosal oral lesions, were enrolled. The bioadhesive gel successfully controlled the post-surgical pain; at 1-week follow-up visit, no signs of infection nor side effects were reported and the surgical sites were completely healed. The bioadhesive gel resulted in a very promising agent for the post-operative management of oral biopsy site, without the need for surgical suture and chlorhexidine applications.

Key words: Bioadhesive gel; Essential oils; Pain; Oral biopsy; Wound healing.

Introduction

A mucosal biopsy is a medical procedure where a fragment (incisional biopsy) or the entire (excisional biopsy) mucosal lesion is surgically collected to establish the histopathological diagnosis. This examination is the gold standard in terms of diagnostic sensibility and specificity and represents a routine procedure in oral medicine (1). Under local anesthesia, a scalpel blade or a punch are usually employed to collect the tissue, and the surgical suture is often placed. The post-operative management includes the application of topical antibacterial gel over the wound, and the control of post-operative pain using non steroidal anti-inflammatory drug (NSAID), as needed by the patient.

Despite a plethora of studies recognizes chlorhexidine as the the most effective molecule among antiseptic agents (2), it is not exempted from adverse effects, most frequently represented by dental and mucosal stainings, long-lasting dysgeusia, burning sensation (3,4) and increased calculus deposition on tooth surfaces (5). Some *in vitro* studies also showed cytotoxic effects against human fibroblasts and lymphocytes, via oxidative stress pathways (6,7). Besides chlorhexidine, even the suture can be associated with complications, such as the bacterial colonization of the filaments which can occur with all type of suture, but increases while considering poly-filament, because of the micro-retaining pattern of the surface (8,9). Nonetheless, the suture often represents a source of stress and anxiety for patients.

To overcome chlorhexidine and suture limitations, the alternative use of natural products, in particular

originating from plants, has been widely investigated, taking advantage from their bioactivities. Among the others, essential oils (EOs) showed many biological properties, such as the antioxidant, anti-inflammatory and analgesic ones. Considering plants belonging to the Myrtaceae family, the extract from Manuka (*Leptospermum scoparium*) has shown the capacity to reduce free radicals and antibacterial effects, as well (10). Similarly, *Eucalyptus* spp. displayed antioxidant, cytoprotective and antibacterial properties, too (11,12). Tea tree (*Melaleuca alternifolia*), another plant belonging to this family, is also characterized by anti-fungal (13), anti-inflammatory (14) and anti-bacterial effects (15,16). Similarly, plant the extracts from the family of Lamiales, including *Thymus vulgaris* and *Mentha piperita*, exhibited *in vitro* antioxidant (17), antifungal and anti-cancer (18, 19) activities, as well as analgesic effects against inflammatory pain (20). The same effects have been reported for *Commiphora myrrha* (21) and Licorice (*Glycyrrhiza glabra*) extracts (22). Among isolated compounds, (-)- α -bisabolol, the main component of the EO from *Matricaria chamomilla*, showed anti-bacterial, anti-mutagenic, anti-inflammatory, analgesic and cicatrizing properties (23,24), while anethole, from *Anethum graveolens* and *Illicium verum*, exhibited anesthetic and antioxidant effects (20,25), and decreased the synthesis and the release of several inflammatory mediators, thus explicating antinociceptive activity (26). Allantoin, physiologically present in a human body and in plants, especially in *Symphytum officinale* leaves, can further promote wound healing and stimulate cell mitosis (27,28), displayed analgesic (29), anti-inflammatory

and moisturizing effects (27), with a certain keratolytic activity (30).

A mixture of the above reported EOs and isolated phytochemicals could act in synergy to promote wound healing and show anti-inflammatory effects. Therefore, the aim of this study was to evaluate the efficacy of a topically applied bioadhesive gel, containing a mix of EOs as active ingredients, in terms of pain control and wound healing after oral biopsies.

Materials and Methods

Study design

This was a pilot study, as the first stage of Phase II clinical trial, non-controlled and non-randomized, to preliminarily investigate pain control and wound healing effects of an EOs-based bioadhesive gel (Hobagel Plus®, HOBAMA S.r.l. Milano) after oral mucosa biopsies. This study was conducted at the dental clinic of the UO Odontostomatologia II, ASST Santi Paolo e Carlo - San Paolo Hospital (University of Milan), where the interventions were performed and data collected and examined. The study included two phases: the former involved the surgical procedure and patient instructions for gel application; the latter involved the clinical follow-up visits and the recording of questionnaires.

Patient recruitment

From January 2018 to February 2018, ten patients referring to the dental clinic were recruited, in full accordance with ethical principles of the World Medical Declaration of Helsinki and under the approval of local Ethics Committee (ASST Santi Paolo e Carlo). Patients were consecutively enrolled during the first visit at the oral medicine unit. Inclusion criteria were being at least 18-years old and needing excisional or incisional oral biopsies (≤ 6 mm in diameter) for the histopathological diagnosis of oral mucosal lesions. Exclusion criteria included uncontrolled hypertension, uncontrolled diabetes, coagulation disorders, and absolute contraindications to surgery, pregnancy, and breastfeeding. Written informed consent of each patient was signed.

Personal and clinical data recording

For each patient, demographic and medical data were recorded during the first visit. An expert clinician, after having evaluated patient's eligibility to the study, performed the intraoral examination.

Intervention

Oral mucosal biopsies were carried out by trained practitioners. All surgical procedures were performed under local anesthesia, after obtaining written surgical consent. At the end of the surgical intervention, hemostasis was obtained with gauze soaked with the physiological saline solution, then, the surgical site was covered with a layer of gel (Hobagel Plus®, HOBAMA S.r.l. Milano). The gel contained Melaleuca Alternifolia Leaf Oil, Leptospermum Scoparium Branch/Leaf Oil, Ammonium Glycyrrhizate, Thymus Vulgaris Oil, Menthol, Mentha Piperita Oil, Eucalyptol, Anethole, Commiphora Myrrha Oil, Bisabolol, Tocopheryl Acetate, Allantoin, Cetylpyridinium Chloride, Hydrogen Peroxide, Sodium Hyaluronate Hydrolyzed, Sodium Hyaluro-

nate and Triclosan as active ingredients, while Calcium/Sodium PVM/MA Copolymer, Paraffinum Liquidum, Petrolatum, Cellulose Gum, Polyvinylpyrrolidone as excipients.

Each patient was instructed to apply a thin layer of gel to the surgical wound, three times a day for one week. Clinical digital photographs of the surgical site were taken, using a reflex digital camera (Nikon D5300, 85 mm Micro Nikkor Af-s Lens, Metz 15 MS-1 digital Speedlight), after the biopsy and soon after topical gel application. Ordinary postoperative instructions were provided to the patient, as follows: do not disturb the area of surgery; do not spit or rinse the mouth for at least 24 hours; brush the teeth gently, taking care to not traumatize the surgical site; avoid physical activity for the first 48 hours; avoid hot/crunchy liquids or foods; if active bleeding would start, keep firm pressure by a gauze soaked with physiological saline solution for 15 minutes, and, in case of persisting bleeding, apply constant pressure at the surgical site for 15 minutes using a tranexamic acid-soaked gauze. Acetaminophen 1000 mg tablets (max. three times a day) was prescribed with the recommendation to be used just as needed. After the biopsy, the patient also received the questionnaire to be filled during the following week, which included recordings about: daily pain (using Visual Analog Scale - VAS), eventual painkillers intake, presence of edema, secondary bleeding, and possible adverse reactions to the gel.

A follow-up visit was carried out one week later. Clinical photographs of the surgical site were taken again, as described above. An expert clinician (S.D.) performed the intraoral examination, particularly focused on the surgical site, recorded the presence/absence of infection or bleeding, and evaluated the wound healing in term of re-epithelization or presence of fibrin clot.

Primary outcome: pain

Pain intensity was assessed by visual analog scale (VAS). VAS is structured as a 100 mm horizontal line with two stop lines at the endings, which represent respectively "no pain" (left extreme) and "the worst pain conceivable" (right extreme). The patients were instructed to mark the VAS daily, always at the same hour. The VAS score was measured in millimeters, using a ruler, as the distance between the starting point of the 100 mm line and the patient's mark (31). In accordance with Jensen *et al.* (32), VAS scores were further divided into four categories to quantify the postoperative pain: from 0 to 4 mm = no pain, from 5 to 44 mm = mild pain, from 45 to 74 mm = moderate pain, from 75 to 100 mm = severe pain. Furthermore, the patients were instructed to record, daily, on the specific questionnaire section, the possible acetaminophen intake.

Secondary outcomes: infection, bleeding, and wound healing

Since the presence of infection, persistent inflammation and bleeding can contribute to the late repair of the surgical site, all these factors were assessed by the patient day-to-day, and by the clinician at 1-week follow-up. In particular, dichotomic visual analysis (presence/absence) of bleeding and edema was recorded every day by the patients throughout specific questionnaire

sections. At 1-week follow up visit, a trained clinician (S.D.) visually verified the presence of local bleeding, edema, and signs of infection, and assessed the wound healing, in term of re-epithelization or presence of fibrin clot, comparing the surgical site with previous clinical photographs.

Results

Ten patients, requiring oral mucosa biopsies, participated to the study: nine females and one male (age range: 44-85 years, mean± SD: 65.7±11.3 years). In four patients, double biopsies were required for the accurate histopathological diagnosis, basing on the clinical features of the mucosal lesions, 14 surgical sites were, thus, considered in this trial. Clinical data are summarized in table 1.

Five biopsies were taken from the palatal mucosa and seven from the keratinized gingiva/alveolar mucosa, while in one case from the lingual margin and in a further one from the soft palate. In two patients were performed excisional biopsies as diagnostic and therapeutic procedure (excisional biopsy), while in the other ones a fragment of the lesion was removed for just diagnostic purposes (incisional biopsy).

In all case, the EOs-based gel showed high and long-lasting bioadhesion, remaining in place for several minutes after a single application.

Primary outcome: pain - During the week following the procedure, each patient was asked to record daily the level of pain using VAS, the presence/absence of secondary bleeding, the presence/absence of edema, painkillers use and experience of adverse reactions to the gel. In five cases, a mild level of pain was reported: 3 of them recorded mild pain just during the day of the intervention (patients number 3, 9, and 10 – Table 1), another one exclusively during eating and speaking, and the pain lasted for the following four days (patient number 2 – Table 1), a further patient reported mild pain when wearing the denture. In the latter case, a double biopsy was performed at the hard palate, localized exactly on the mucosa under denture bases (patient number 5 - Table 1). The remaining five patients reported no pain during the week after surgery. After the fifth day, all patients did not record any pain.

Mean VAS values, reported each day after the biopsy for one week, are shown in Figure 1. Overall, a mild pain resulted during the same day of the intervention (day 0), while from postoperative day 1 to day 6 no pain

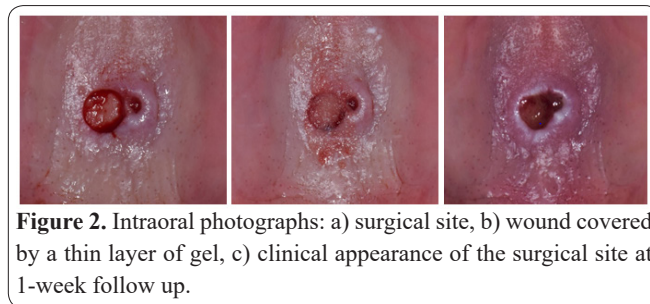
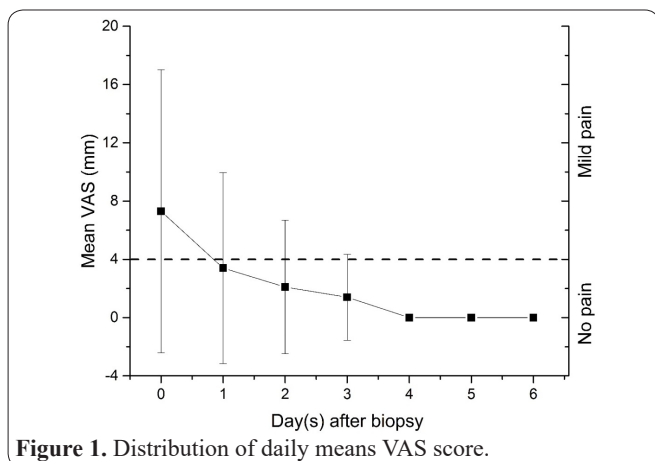


Figure 2. Intraoral photographs: a) surgical site, b) wound covered by a thin layer of gel, c) clinical appearance of the surgical site at 1-week follow up.

was recorded. None of the patients reported the use of acetaminophen or other painkillers.

Secondary outcomes: infection, bleeding, and wound healing

The gel, placed after gauze compression on the surgical site, successfully controlled post-operative bleeding in all patients (Fig. 2a and b). Only one patient reported a light edema at the surgical site soon after the biopsy, which resolved within the first 2 days (patient number 3 – Table 1).

In terms of secondary bleeding, two patients reported one episode during the first day: one of them occurred two hours after the surgery, while the patient was eating, and was easily controlled by the compression of the site with saline impregnated gauze (patient number 1 – Table 1). The other case of secondary bleeding occurred after the patient had performed physical activity and taken his dinner, thus largely increased the risk of this complication. The same patient controlled the bleeding using tranexamic acid-soaked gauze, instead of a saline one as we recommended (patient number 10 – Table 1).

None of the patients enrolled reported adverse events to the gel.

At 1-week follow-up visit, no signs of infection at the surgical sites could be observed (Figure 1c). In 10 surgical sites, complete or partial re-epithelization occurred, in other 4 the presence of fibrin clot could be detected (Figure 2c, as an example).

Discussion

The need of new agents as alternatives to surgical suture and chlorhexidine is still demanding, and, in recent decades, high attention has been directed towards several plant-derived compounds with antiseptic, anti-inflammatory and wound healing properties. The aim of chlorhexidine application over the suture is to reduce bacterial colonization of filaments (9,33), usually associated with both aerobic (*Streptococcus* spp., *Staphylococcus warneri*, *Neisseria* spp., *Actinomyces* spp., *Pasteurella* spp.) and anaerobic (*Veillonella parvula*, *Peptostreptococcus* spp., *Actinobacillus* spp., *Prevotella* spp., *Fusobacterium* spp.) microorganisms. Chlorhexidine, however, has the major drawbacks to stain oral hard and soft tissue and to modify the perception of taste (34,35). Recently, Vouzara and colleagues (36) demonstrated its cytotoxicity, which resulted significantly higher than sodium hypochlorite and ethylenediaminetetraacetic acid. Hidalgo et al. (6) found that chlorhexidine produced mitochondrial injury and had anti-proliferative effects against human fibroblasts, consistently with Salimi and colleagues (7) who demonstrated its cytotoxicity in human lymphocytes.

Table 1. Demographic and clinical data of patients enrolled in the study. *Excisional biopsy: the lesion is completely removed; incisional biopsy: a tissue fragment of the lesion is collected.

Patient	Gender	Age	Site	Biopsy Type*	Multiple biopsies	Adverse events	Pain		Bleeding	
							During the week	At 1-week follow up	During the week	At 1-week follow up
1	male	70	hard palate	incisional	-	none	no	no	yes	no
2	female	73	lateral surface of the tongue	incisional	-	none	mild	no	no	no
3	female	71	mandibular attached gingiva/alveolar mucosa	incisional	2	none	mild	no	yes	no
4	female	68	hard palate	incisional	2	none	no	no	no	no
5	female	85	hard palate	incisional	-	none	mild	no	no	no
6	female	71	maxillary attached gingiva/alveolar mucosa	incisional	2	none	no	no	no	no
7	female	61	soft palate	excisional	-	none	no	no	no	no
8	female	44	lingual aspect of the attached gingiva	excisional	-	none	no	no	no	no
9	female	58	maxillary attached gingiva/alveolar mucosa	incisional	2	none	mild	no	no	no
10	female	56	hard palate	incisional	-	none	mild	no	no	No

This pilot study demonstrated the promising effects of a high bioadhesive gel containing a mixture of EOs in controlling post-operative inflammation and wound healing after minor surgery, i.e. oral mucosal biopsies. Noteworthy, just two patients out ten reported a mild pain up to three days from intervention, three patients reported mild pain just for one day, while, in the remaining 5, no pain was ever perceived. This finding was consistent with the findings reported by Kearns and Lodi (37,38). Interestingly, none of the patients, in the current study, declared the use of painkillers after the intervention. This finding indicates a better outcome than data available from the literature, which reports about 18-26% of patients taking painkillers after oral mucosa biopsies, usually during the same day of surgery (38,39). One week later, 10 surgical sites experienced partial or complete re-epithelization, while the remaining ones had a stable fibrin clot; in all cases, no signs of infection were detectable. Interestingly, partial or complete re-epithelization of surgical wounds occurred in five patients out six who were affected by immune-mediated inflammatory oral mucosal diseases (oral lichenoid lesions, mucous membrane pemphigoid, and oral lichen planus).

All these findings might be ascribed to the strong bioadhesion of the gel and to the synergic effects of its active ingredients. The Manuka EO, indeed, possesses high antioxidant and antibacterial properties, even against Methicillin-Resistant *Staphylococcus Aureus* (MRSA) (39), besides anti-inflammatory activity, reducing migration of inflammatory cells at the wound site and stimulating the proliferation of fibroblasts and epithelial cells (10). Similarly, to Manuka EO, *Thymus vulgaris* and *Melaleuca alternifolia* EOs showed high antibacterial and antioxidant properties (16, 18). Terpinen-4-ol, a component of many EOs, is one of the most investigated compounds and evidence suggests that it can suppress inflammatory mediators by monocytes, and reduce histamine-induced skin inflammation (40,41). Nogueira (14) investigated the capacity of terpinen-4-ol and α -terpineol (another EO constituent) to modulate macrophage response towards bacterial stimulation and found that these compounds significantly reduce the production of several interleukins (IL-1 β , IL-6, IL-8, and IL-10). Furthermore, EO from *Mentha piperita*, mainly composed by menthol, exhibited anti-inflammatory properties, too, as shown in animal models, by inhibiting the production of nitric oxide and prostaglandin E2 in lipopolysaccharide-activated macrophages (42). A review by de Cassia (20) reported, in particular, a significant analgesic activity of menthol in controlling acute and inflammatory pain. This could act in combination with both (-)- α -bisabolol (24), *Commiphora myrrha* (21), allantoin (20), anethole and licorice (27,43), which display analgesic activity together with anti-inflammatory and wound healing effects.

No adverse events were found. One case of post-operative swelling occurred in a patient affected by a chronic inflammatory oral disease (oral lichen planus), which could have exacerbated the response to surgical trauma. Just two cases of minor secondary bleeding, during the same day of the intervention, were reported, but they could be explained since patients disobeyed the post-surgical instructions provided by the clinician. Indeed, one patient reported that the bleeding occurred

while he was eating crunchy food in the same day of surgery, while the second one carried out intense physical activity, and, again, the bleeding occurred while eating.

Within the limitations of this pilot study (having little sample size and following a not controlled and not randomized design), the here proposed EOs-based bioadhesive gel may represent a promising alternative to the use of suture and chlorhexidine, promoting wound healing, showing anti-inflammatory effects, and reducing operative time, patient distress, and chlorhexidine side effects as well. It may be particularly useful in those cases difficult to suture (for example gingiva and hard palate mucosa), or in presence of highly inflamed and friable tissue. The further second stage of this Phase II clinical trial is needed to better explore these preliminary findings, especially throughout the controlled randomized clinical trial on large patient population.

Acknowledgments

Authors are grateful to Toni Baroni and HOBAMA S.r.l group for providing the Hobagel Plus® used during the trial.

Conflicts of interest

The authors declare no conflict of interest.

Author's contributions

GL conceived the study design, FS and SD performed the biopsies and collected the data, SD executed the follow-up visits. FS, SD, and EV analyzed the data and drafted the article, GL, AS and MI critically reviewed the article. All authors approved the final version to be published.

References

1. Mota-Ramírez A, Silvestre FJ, Simó JM. Oral biopsy in dental practice. *Med Oral Patol Oral Cir Bucal*. 2007 Nov 1;12(7):E504-510.
2. Varoni E, Tarce M, Lodi G, Carrassi A. Chlorhexidine (CHX) in dentistry: state of the art. *Minerva Stomatol*. 2012 Sep;61(9):399-419.
3. Marinone MG, Savoldi E. Chlorhexidine and taste. Influence of mouthwashes concentration and of rinsing time. *Minerva Stomatol*. 2000 May;49(5):221-226.
4. Flötra L, Gjermo P, Rölla G, Waerhaug J. Side effects of chlorhexidine mouth washes. *Scand J Dent Res*. 1971;79(2):119-125.
5. Richards D. Chlorhexidine mouthwash plaque levels and gingival health. *Evid Based Dent*. 2017 Jun 23;18(2):37-38.
6. Hidalgo E, Dominguez C. Mechanisms underlying chlorhexidine-induced cytotoxicity. *Toxicol In Vitro*. 2001 Aug-Oct;15(4-5):271-276.
7. Salimi A, Alami B, Pourahmad J. Analysis of cytotoxic effects of chlorhexidine gluconate as antiseptic agent on human blood lymphocytes. *J Biochem Mol Toxicol*. 2017 Aug;31(8).
8. Banche G, Roana J, Mandras N, Amasio M, Gallesio C, Allizond V et al. Microbial adherence on various intraoral suture materials in patients undergoing dental surgery. *J Oral Maxillofac Surg*. 2007 Aug;65(8):1503-1507.
9. Grigg TR, Liewehr FR, Patton WR, Buxton TB, McPherson JC. Effect of the wicking behavior of multifilament sutures. *J Endod*. 2004 Sep;30(9):649-652.
10. Alvarez-Suarez JM, Gasparrini M, Forbes-Hernández TY, Maz-

- zoni L, Giampieri F. The Composition and Biological Activity of Honey: A Focus on Manuka Honey. *Foods*. 2014 Jul 21;3(3):420-432.
11. Rocha Caldas GF, Oliveira AR, Araújo AV, Lafayette SS, Albuquerque GS, Silva-Neto Jda C, Costa-Silva JH, Ferreira F et al. Gastroprotective Mechanisms of the Monoterpene 1,8-Cineole (*Eucalyptol*). *PLoS One*. 2015 Aug 5;10(8):e0134558.
 12. Abd El-Moneim MR, Fatma SA, Turkey AF. Control of *Tetranychus urticae* Koch by extracts of three essential oils of chamomile, marjoram and *Eucalyptus*. *Asian Pac J Trop Biomed*. 2012 Jan;2(1):24-30.
 13. Tobouti PL, Mussi MC, Rossi DC, Pigatti FM, Taborda CP, de Assis Taveira LA et al. Influence of melaleuca and copaiba oils on *Candida albicans* adhesion. *Gerodontology*. 2016 Sep;33(3):380-385.
 14. Nogueira MN, Aquino SG, Rossa Junior C, Spolidorio DM. Terpinen-4-ol and alpha-terpineol (tea tree oil components) inhibit the production of IL-1 β , IL-6 and IL-10 on human macrophages. *Inflamm Res*. 2014 Sep;63(9):769-778.
 15. Santamaria M Jr, Petermann KD, Vedovello SA, Degan V, Lucato A, Franzini CM. Antimicrobial effect of *Melaleuca alternifolia* dental gel in orthodontic patients. *Am J Orthod Dentofacial Orthop*. 2014 Feb;145(2):198-202.
 16. Sharifi-Rad J, Salehi B, Varoni EM, Sharopov F, Yousaf Z, Ayatollahi SA et al. Plants of the *Melaleuca* Genus as Antimicrobial Agents: From Farm to Pharmacy. *Phytother Res*. 2017 Oct;31(10):1475-1494.
 17. Mamadalieva NZ, Youssef FS, Ashour ML, Sasmakov SA, Tiezzi A, Azimova SS. Chemical composition, antimicrobial and antioxidant activities of the essential oils of three Uzbek *Lamiaceae* species. *Nat Prod Res*. 2018 Feb 22:1-4.
 18. Alexa E, Sumalan RM, Danciu C, Obistioiu D, Negrea M, Poiana MA et al. Synergistic Antifungal, Allelopathic and Anti-Proliferative Potential of *Salvia officinalis* L., and *Thymus vulgaris* L. Essential Oils. *Molecules*. 2018 Jan 16;23(1). pii: E185.
 19. Rozza AL, Meira de Faria F, Souza Brito AR, Pellizzon CH. The gastroprotective effect of menthol: involvement of anti-apoptotic, antioxidant and anti-inflammatory activities. *PLoS One*. 2014 Jan 21;9(1):e86686.
 20. de Cássia da Silveira E, Sá R, Lima TC, da Nóbrega FR, de Brito AEM, de Sousa DP. Analgesic-Like Activity of Essential Oil Constituents: An Update. *Int J Mol Sci*. 2017 Dec 9;18(12). pii: E2392.
 21. Mahmoud AM, Zaki AR, Hassan ME, Mostafa-Hedeab G. *Commiphora molmol* resin attenuates diethylnitrosamine/phenobarbital-induced hepatocarcinogenesis by modulating oxidative stress, inflammation, angiogenesis and Nrf2/ARE/HO-1 signaling. *Chem Biol Interact*. 2017 May 25;270:41-50.
 22. Dastagir G, Rizvi MA. Review - *Glycyrrhiza glabra* L. (Licorice). *Pak J Pharm Sci*. 2016 Sep;29(5):1727-1733.
 23. Woollard AC, Tatham KC, Barker S. The influence of essential oils on the process of wound healing: a review of the current evidence. *J Wound Care*. 2007 Jun;16(6):255-257.
 24. Hartman D, Coetzee JC. Two US practitioners' experience of using essential oils for wound care. *J Wound Care*. 2002 Sep;11(8):317-320.
 25. Ghelardini C, Galeotti N, Mazzanti G. Local anaesthetic activity of monoterpenes and phenylpropanes of essential oils. *Planta Med*. 2001 Aug;67(6):564-566.
 26. Ritter AM, Domiciano TP, Verri WA Jr, Zarpelon AC, da Silva LG, Barbosa CP et al. Antihypernociceptive activity of anethole in experimental inflammatory pain. *Inflammopharmacology*. 2013 Apr;21(2):187-197.
 27. Araújo LU, Grabe-Guimarães A, Mosqueira VC, Carneiro CM, Silva-Barcellos NM. Profile of wound healing process induced by allantoin. *Acta Cir Bras*. 2010 Oct;25(5):460-466.
 28. Loots JM, Loots GP, Joubert WS. The effect of allantoin on cellular multiplication in degenerating and regenerating nerves. *S Afr Med J*. 1979 Jan 13;55(2):53-56.
 29. Shestopalov AV, Shkurat TP, Mikashinovich ZI, Kryzhanovskaia IO, Bogacheva MA, Lomteva SV et al [Biological functions of allantoin]. *Izv Akad Nauk Ser Biol*. 2006 Sep-Oct;(5):541-545.
 30. Veraldi S, Menter A, Innocenti M. Treatment of mild to moderate seborrheic dermatitis with MAS064D (Sebclair), a novel topical medical device: results of a pilot, randomized, double-blind, controlled trial. *J Eur Acad Dermatol Venereol*. 2008 Mar;22(3):290-296.
 31. Kjeldsen HB, Klausen TW, Rosenberg J. Preferred Presentation of the Visual Analog Scale for Measurement of Postoperative Pain. *Pain Pract*. 2015 Aug 27.
 32. Jensen MP, Chen C, Brugger AM. Interpretation of visual analog scale ratings and change scores: a reanalysis of two clinical trials of postoperative pain. *J Pain*. 2003 Sep;4(7):407-414.
 33. Otten JE, Wiedmann-Al-Ahmad M, Jahnke H, Pelz K. Bacterial colonization on different suture materials--a potential risk for intra-oral dentoalveolar surgery. *J Biomed Mater Res B Appl Biomater*. 2005 Jul;74(1):627-635.
 34. al-Tannir MA, Goodman HS. A review of chlorhexidine and its use in special populations. *Spec Care Dentist*. 1994 May-Jun;14(3):116-122.
 35. Autio-Gold J. The role of chlorhexidine in caries prevention. *Oper Dent*. 2008 Nov-Dec;33(6):710-716.
 36. Vouzara T, Koulaouzidou E, Ziouti F, Economides N. Combined and independent cytotoxicity of sodium hypochlorite, ethylenediaminetetraacetic acid and chlorhexidine. *Int Endod J*. 2016 Aug;49(8):764-773.
 37. Kearns HP, McCartan BE, Lamey PJ. Patients' pain experience following oral mucosal biopsy under local anaesthesia. *Br Dent J*. 2001 Jan 13;190(1):33-35.
 38. Lodi G, Sardella A, Demarosi F, Canegallo L, Moneghini L, D'Orefice S et al. Oral biopsy. A prospective study on 286 consecutive procedures. *Minerva Stomatol*. 2007 May;56(5):241-251.
 39. Blaser G, Santos K, Bode U, Vetter H, Simon A. Effect of medical honey on wounds colonised or infected with MRSA. *J Wound Care*. 2007 Sep;16(8):325-328.
 40. Halcón L, Milkus K. *Staphylococcus aureus* and wounds: a review of tea tree oil as a promising antimicrobial. *Am J Infect Control*. 2004 Nov;32(7):402-408.
 41. Carson CF, Hammer KA, Riley TV. *Melaleuca alternifolia* (Tea Tree) oil: a review of antimicrobial and other medicinal properties. *Clin Microbiol Rev*. 2006 Jan;19(1):50-62.
 42. Sun Z, Wang H, Wang J, Zhou L, Yang P. Chemical Composition and Anti-Inflammatory, Cytotoxic and Antioxidant Activities of Essential Oil from Leaves of *Mentha piperita* Grown in China. *PLoS One*. 2014 Dec 10;9(12):e114767.
 43. Yang R, Yuan BC, Ma YS, Zhou S, Liu Y. The anti-inflammatory activity of licorice, a widely used Chinese herb. *Pharm Biol*. 2017 Dec;55(1):5-18.