

Epidermolytic acanthoma in a young woman: A case letter

Peng Zhao, Xiaowei Qin, Junxia Qin, Lifang Chen*

Department of Dermatology, Shanxi Provincial People's Hospital, Taiyuan, 030012, China

*Correspondence to: chlf2006@sohu.com

Received April 1, 2020; Accepted June 12, 2020; Published September 30, 2020

Doi: <http://dx.doi.org/10.14715/cmb/2020.66.6.4>

Copyright: © 2020 by the C.M.B. Association. All rights reserved.

Abstract: Epidermolytic acanthoma (EA) is a rare benign tumor that is characterized by epidermolytic hyperkeratosis on histopathology. It usually presents in adulthood as an asymptomatic tumor <1 cm in diameter with a verrucous surface. We report a very uncommon case of epidermolytic acanthoma. A 21-year-old woman came to our hospital with a pale black papule on the left lower eyelid near the Inner canthus for 2 months. Two months ago the patient noted a pale brown spot on the inside of the left lower eyelid, which gradually enlarged, forming a papule with a deepened color. There were no associated symptoms, such as itching or pain. There were no local injuries, scratches, or other incidents before the crash occurred. The patient was always healthy, with no history of chronic disease or other skin diseases, and no similar cases existed in the family. We diagnosed it as EA.

Key words: Epidermolytic acanthoma; Epidermolytic hyperkeratosis; Tumor.

Introduction

Epidermolytic acanthoma (EA) was first described by Shapiro and Baraf in 1970 (1). Epidermolytic acanthoma is a rare, benign, acquired, and asymptomatic lesion that usually appears in middle age or later. It usually appears in a single form, but may appear in the form of multiple or diffuse discrete lesions (2). It is more common in men and is typically manifested as papules with hyperkeratosis of the trunk or extremities. However, epidermolytic acanthoma has been reported in multiple locations including the face and genitals. Most cases of multiple lesions have been reported in the genital area, mainly the scrotum. In addition, the lesions may appear

as linear plaques instead of isolated papules, which has been reported in the vulvar region (3). In this paper, we report Epidermolytic acanthoma in a young woman.

Case report

The physical examination revealed no obvious abnormalities. The dermatologic examination showed a dark papillomatous papule (4×3 mm) with uneven color and a smooth surface near the inner canthus of the left lower eyelid (Fig.1). The dermoscopic examination showed skin color and a pale white background with black globules of different sizes, stains with uneven shades of brown, and linear, globular blood vessels (Fig.2). The pathological examination of the skin

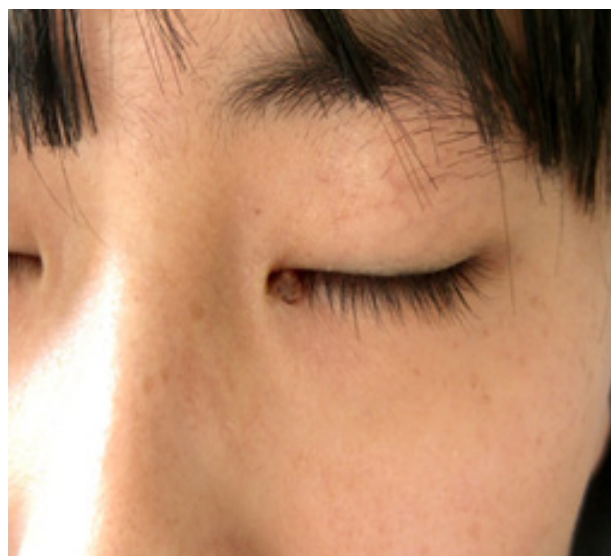

Figure 1. Pale black papillomatous papules on the left lower eyelid near the inner canthus.

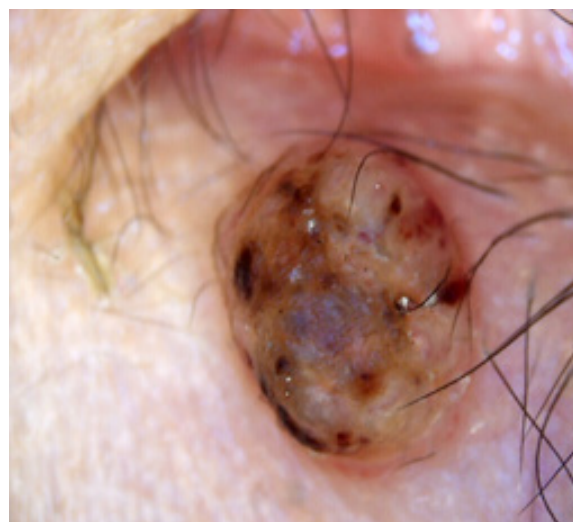


Figure 2. Dermoscopy (30×): black globules of varying sizes, dark brown stains, and linear and globular blood vessels observed on a pale white background.

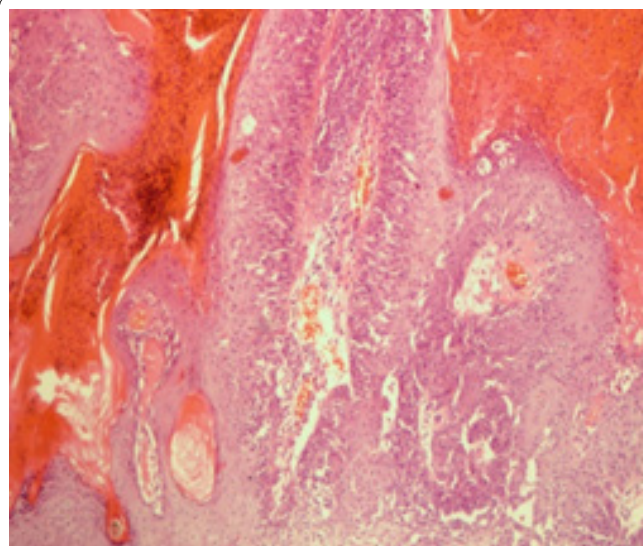


Figure 3. Skin histopathology (HE, 40×): hyperkeratosis accompanied by incomplete keratosis, papillary hyperplasia, and epidermolysis.

demonstrated hyperkeratosis, papillary hyperplasia, epidermolysis, granular and acanthocyte layers, vacuolation, granular degeneration, and thick keratin particles in the granular layer (Fig. 3).

Diagnose: Epidermolytic acanthoma

Treatment involved in surgical excision. The follow-up evaluation at 3 months suggested that the incision had healed well without recurrence of local skin lesions (Fig.4).

Discussion

Epidermolytic acanthoma can be divided into two types (single and multiple types). The single type usually occurs on the face, trunk, extremities, and genitals. The multiple types are common in the genitals (4). Generally, there are no symptoms, except for pruritus in a small percentage of epidermolysis acanthoma patients. A retrospective study showed that the average age of onset for multiple epidermolysis acanthoma is 51 years

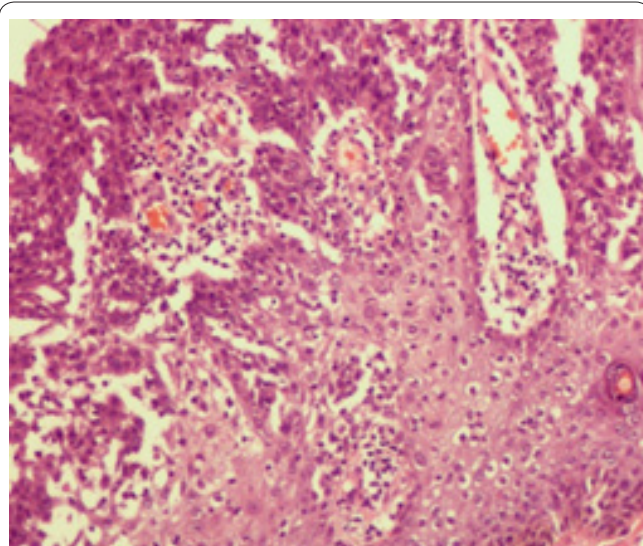


Figure 4. Skin pathology (HE * 100): vacuolar and granular degeneration of the granular and spinous cell layers.

and the male-to-female ratio is 3:1 (5). The etiology of epidermolysis acanthoma remains unclear. Studies have shown that the expression of keratin K 1 and K10 is abnormal in epidermolysis acanthoma lesions. Some reports suggest that K1 and K10 may be associated with injury, immunosuppression, and ultraviolet radiation (4). Some scholars believe that the epidermolysis acanthoma may be the result of re-exposure to injury and other factors in addition to K1 and K10 gene mutations. Most studies have shown that the lesions test negative for HPV, but Jung *et al* (6) reported a case of HPV 16-positive scrotal epidermolysis acanthoma. Clinically, it is necessary to differentiate epidermolysis acanthoma from viral warts, seborrheic keratosis, and pigmented nevus. Mittal and Mahapatra (7) reported a case of a 63-year-old male patient with epidermolysis acanthoma involving the eyelid. Our current case was a 21-year-old female who was younger than previously reported patients. The lesion was located on the left lower eyelid and not associated with local trauma, sun exposure, or a history of scratches before onset. The patient did not apply eye shadow or mascara.

References

1. Shapiro L, Baraf CS. Isolated epidermolytic acanthoma. A solitary tumor showing granular degeneration. *Arch Dermatol* 1970; 101(2): 220–3.
2. Phung TL, Wright TS, Pourciau CY, Smoller BR. Tumors of the Cutaneous Appendages and the Epidermis. In *Pediatric Dermatopathology 2017* (pp. 505-527). Springer, Cham.
3. Billings SD. Tumors and tumorlike conditions of the skin. Rosai and Ackerman's *Surgical Pathology E-Book*. 2017 Oct 25:44.
4. Rojhirunsakool S, Jirasuthat S, Chanprapaph K. Epidermolytic Acanthoma on Fingers, Mimicking Flat Warts. *Case Rep Dermatol* 2017; 9(2):98-101.
5. Lee TJ, Wu YH. Multiple epidermolytic acanthomas mimicking condyloma: a retrospective study of 8 cases. *Int J Dermatol* 2018; 57(1):28-3.
6. Jung JM, Lee SH, Won CH, Chang SE, Lee MW, Choi JH, Moon KC. A Case of Multiple Epidermolytic Acanthoma of the Scrotum: Is the Human Papillomavirus a Culprit? *Ann Dermatol* 2015; 27(5):633-4.
7. Mittal R, Mahapatra S. Acantholytic Acanthoma of the Eyelid: Unusual Presentation. *Ophthal Plast Reconstr Surg* 2016; 32(4): e94-5.