



Comparison of pulpal vitalization and root canal therapy in symptomatic immature permanent molars

Jian Xia Guang*, Junke Li, Shiling Guo

Department of Oral Medicine, Hebei Eye Hospital, Xingtai 054001, China

ARTICLE INFO

Original paper

Article history:

Received: August 25, 2021

Accepted: January 28, 2022

Published: February 28, 2022

Keywords:

CEM Cement, MTA

Pulpotomy, Vital Pulp Therapy, Toll-like Receptor, Root Canal Therapy

ABSTRACT

Endodontic treatment of immature permanent teeth has various problems. Today, the primary goal in the treatment of such teeth is to preserve the life of the pulp so that roots can develop entirely and naturally. If vital pulp therapy can treat these teeth, the treatment will be simpler and less expensive. Therefore, this study compared vital pulp therapy (including calcium-enriched mixture (CEM) cement and MTA methods) and root canal therapy (RCT) in symptomatic immature permanent molars. Also, the expression of TLR-2 and TLR-4 was evaluated in the gingival tissue of patients for further evaluation. In this clinical trial study, 615 patients randomly received three treatments: pulpotomy with CEM (205 cases), pulpotomy with MTA (207 cases), and root canal therapy (203 cases). The presence of periapical lesion was evaluated radiographically at three-time points: start, six months, and 12 months after treatment. The expression of TLR-2 and TLR-4 was also evaluated in the gingival tissue of patients by the Real-time PCR technique. The one-year follow-up of the periapical index shows that the presence of periapical lesion at six-month follow-up in the three groups of MTA, CEM, and RCT equals 14 cases (8%), 7 cases (4%), and 40 cases (22%). The one-year follow-up equals 12 cases (7%), 9 cases (5%), and 33 cases (18%), respectively. The TLR-2 and TLR-4 gene expression results showed no statistical difference between the three groups (CEM, MTA, and RCT). Still, one year after treatment, there was a statistically different between vital pulp therapy (CEM and MTA) and root canal therapy ($P < 0.05$). Also, the results showed no statistical difference between CEM and MTA treatment in terms of TLR-2 and TLR-4 gene expression before and one year after treatment. In general, the results showed that pulpotomy treatment using two biomaterials, CEM and MTA, is more successful than RCT treatment.

DOI: <http://dx.doi.org/10.14715/cmb/2022.68.2.25>

Copyright: © 2022 by the C.M.B. Association. All rights reserved.



Introduction

Endodontic treatment of immature permanent teeth has various problems because of incomplete root development and receding canals (1). The larger dimensions of the apical canal area compared to the middle and the coronal regions make it difficult to clear the canal, and the lack of an apical barrier makes it impossible to fill the canal. In addition, the thin dentin walls of the canal are prone to fracture (2). Accordingly, today, the primary goal in treating such teeth is to use live pulp treatment methods or apexogenesis to preserve the life of the pulp and continue the root development wholly and naturally. It is said that this method of pulp healing occurs during the regeneration process and not the repair process (3). The main treatment methods of live pulp are direct pulp cap and pulpotomy (incomplete and complete). In fact, by removing the infected pulp tissue and preserving and separating the healthy pulp tissue from the oral environment, the natural

development of the root is provided (4).

Live pulp treatment or pulpotomy aims to preserve pulp life and stimulate the remaining pulp to repair the structural and functional pulp-dentin complex (5). It means that the tooth pulp survives and regenerates the dentin in the exposure area to cut off the body's internal environment from the oral cavity by creating a biological barrier and preventing the re-invasion of pathogens. In terms of the position of the dental pulp, pulps with traumatic, mechanical, and caries exposure are candidates for pulpotomy treatment (6). This method can also treat permanent teeth with immature or mature roots. Regardless of the tooth's root maturation stage or the type and extent of pulp inflammation, the most critical point in treating live pulp is the current life of the pulp tissue and especially its proper blood supply. Active dentin production requires good tissue blood supply (7). So far, several methods have been proposed to treat exposed pulp. Still, unfortunately, many of these methods are based

*Corresponding author. E-mail: guangjianxia0706@163.com
Cellular and Molecular Biology, 2022, 68(2): 178-182

on clinical experience and unsubstantiated scientific evidence and do not have the necessary validity. Fortunately, the issue of live pulp treatment in dental science is being seriously studied today, especially as to which technique/material leads to better and more predictable restoration (8).

Patients must visit at regular intervals in such studies to control treatment outcomes. Some patients may not be present at any of the follow-up times. Therefore their data will not be available to researchers at the relevant follow-up times, which have occurred in the National Vital Pulp Therapy Project and can be interpreted in terms of results (5). The result has no side effects. Research has shown that in most longitudinal studies, we encounter missing data due to a lack of measurement or recording. Even in controlled situations, lost data occurs due to study protocols or cases people meet (9).

It is hypothesized that if live pulp therapy can be used to treat irreversible pulpitis, more straightforward and less costly treatment would be provided for patients (10). Therefore, this study compared vital pulp therapy (including CEM and MTA methods) and root canal therapy in symptomatic immature permanent molars. Because the Toll-like receptor family (TLRs) is responsible for identifying conserved microbial structures such as lipopolysaccharide (LPS) in bacteria and activates the signaling pathways that ultimately lead to immune responses (11), therefore, in this study, the expression of TLR-2 and TLR-4 was also evaluated in the gingival tissue of patients.

Materials and methods

Studied Patients

The present study was a randomized clinical trial in which 615 patients with symptomatic immature

permanent molars who met the inclusion criteria randomly received three types of treatment after obtaining informed consent from their parents. The first group consisted of 205 patients undergoing pulpotomy with calcium-enriched mixture (CEM) cement. The second group consisted of 207 patients undergoing MTA pulpotomy. The third group consisted of 203 patients who underwent root canal therapy (RCT). For these patients, the indicator of the pericardial lesion (with radiographic diagnosis) was evaluated three times, including start, six months, and one year after treatment. Treatment method and gender were considered independent variables.

Biopsy and Real-time PCR Techniques

Before and one year after treatment, the biopsy site was selected, and then local anesthesia (Injection of 2% lidocaine solution with adrenaline 80,000: 1 and inferior alveolar nerve block) was given as far away from the area as possible. In the next step, a biopsy was taken from the desired areas (2 mm), and after removing the biopsies, the rest of the incision was completed. Tissue samples were stored in RNA solution (Qiagen, Germany) for further stability from the moment of separation until RNA extraction. According to its instructions, RNAs were then extracted from the tissue sample by the RNeasy Mini Kit (Qiagen, Germany). Next, for Real-time PCR, the cDNA was synthesized using a cDNA kit (Fermantase, Germany) and 1µl RNA was used for cDNA synthesis. Two types of primers were designed for TLR-2 and TLR-4 genes. GAPDH gene was also used as a reference (housekeeping) gene. The sequence of primers, product size, and thermocycling conditions are given in Table 1.

Table 1. The sequence of primers, product size, and thermocycling condition of TLR-2, TLR-4, and GAPDH genes

Gene	Primer Sequence (5'-3')	Product Size	Thermocycling Condition
TLR-2	Forward TGTGGATGGTGTGGGTCTTG	940	95°C/2min, 40 cycles of 95°C/30 sec, 58°C/20 sec, and 70°C/30 sec
	Reverse ATATGCAGCCTCCGGATTGT		
TLR-4	Forward ATATTGACAGGAAACCCCATCCA	300	95°C/2min, 40 cycles of 95°C/30 sec, 58°C/20 sec, and 70°C/30 sec
	Reverse AGAGAGATTGAGTAGGGGCATTT		
GAPDH	Forward ATCACTGCCACCCAGAAGACTG	215	95°C/2min, 40 cycles of 95°C/30 sec, 57.5°C/20 sec, and 70°C/30 sec
	Reverse AGGTTTTTCTAGACGGCAGGTCAG		

Statistical analysis

The data distribution was determined using SPSS software version 23 to compare and evaluate the

relationship between the groups. Kolmogorov-Smirnov test was used to examine the data distribution. One-way ANOVA, Chi-square test, and

Tukey's test was used for normal distribution data. Paired Wilcoxon Signed-Rank Test was used to compare data with the abnormal distribution. Differences between data were considered statistically significant when P was less than 0.05.

Results and discussion

At the beginning of the present study, out of 205 patients who underwent pulpotomy with CEM, 63 had periapical lesions. Out of 207 patients who underwent pulpotomy with MTA, 54 had periapical lesions. Out of 203 patients who underwent endodontic treatment, 65 had a periapical lesion. The Chi-square test showed no significant difference in the sex distribution of treatment groups (P = 0.272). Table 2 shows the demographic characteristics of patients in treatment groups. Figure 1 shows the radiography of case No. 250 undergoing MTA pulpotomy.

The one-year follow-up of the periapical index shows that the presence of periapical lesion at six-month follow-up in the three groups of MTA, CEM, and RCT equals 14 cases (8%), 7 cases (4%), and 40 cases (22%). The one-year follow-up equals 12 cases (7%), 9 cases (5%), and 33 cases (18%), respectively (Table 3).

The TLR-2 and TLR-4 gene expression results showed no statistical difference between the three groups (CEM, MTA, and RCT). Still, one year after treatment, there was a statistically different between vital pulp therapy (CEM and MTA) and root canal therapy (P<0.05). Also, the results showed no statistical difference between CEM and MTA treatment in terms of TLR-2 and TLR-4 gene

expression before and one year after treatment (Figure 2).

Table 2. The demographic characteristics of patients in treatment groups

Variables	Treatment Groups			P-value
	RCT	CEM	MTA	
Age (year)	10.56	11.08	11.17	0.829
Gender	Male	82 (40%)	72 (35.1%)	0.273
	Female	121 (60%)	133 (64.9%)	

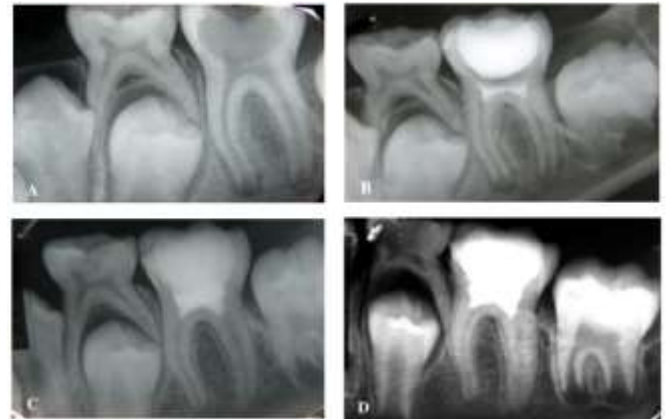

Figure 1. Radiography of case No. 250 undergoing MTA pulpotomy, A: Primary radiography; B: Radiography after epoxogenesis; C: Radiography after 6 months; D: Radiography after 12 months

Table 3. Periapical lesion status at three times in CEM, MTA, and RCT treatment groups in symptomatic immature permanent molars

Treatment Group	Before Treatment			Six Months			Twelve months		
	Have	Not have	Missing Data	Have	Not have	Missing Data	Have	Not have	Missing Data
CEM	63	142	0	14	163	28	12	155	38
MTA	54	153	0	7	176	26	9	170	28
RCT	65	138	0	40	142	21	33	141	19

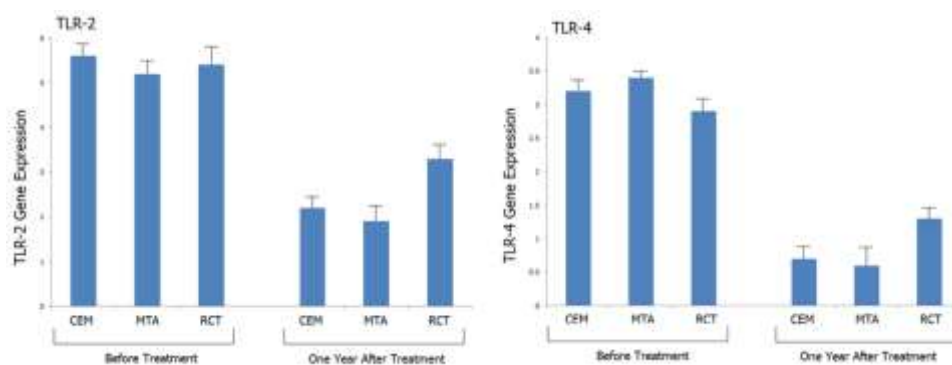


Figure 2. Comparison of TLR-2 and TLR-4 gene expression between CEM, MTA, and RCT treatment groups before and one year after treatment (mean ± SD)

Direct pulp coverage and pulpotomy (incomplete and complete) are the two main methods of treating

live pulp (12). The success of these treatments depends on the accurate and correct diagnosis of the

pulp condition, establishing a suitable seal, and preventing bacterial contamination (13). One of the basic requirements for successful treatment is reversible pulp inflammation and asymptomatic teeth. Even the goal of living pulp treatment is to preserve the life and function of the pulp in cases where the pulp damage is reversible (14). The main difficulty in treating immature permanent teeth is correctly determining the extent and stage of pulp health, followed by the ability to predict the possibility of its recovery (15). It has been said that teeth should not have a history of prolonged pain due to thermal changes. Pain lasting more than a few seconds after applying thermal stimulation may indicate irreversible pulpitis. If the pain is severe and spontaneous, the diagnosis is almost definitive (2).

The typical treatment for irreversible inflammation of the pulp is root canal therapy (RCT), and this treatment is very time-consuming, complex, and expensive, especially when the tooth is molar (16). Therefore, the complexity of the equipment and the high cost of the services may force the patient to extract a tooth (17). Oral health indicators show that the number of extracted teeth is high in many developing and even developed countries. If the new pulpotomy treatment, an easy and cheap method, has successful and appropriate results, a primary treatment need can be met in the country and even in the world (18). In the present study, pulpotomy with CEM and MTA had significantly fewer periapical lesions than the usual treatment method (root canal therapy). At the same time, there was no significant difference between CEM and MTA. Therefore, further research can suggest pulpotomy as the treatment of choice for irreversible pulpitis.

Also, the TLR-2 and TLR-4 gene expression results showed no statistical difference between the three groups (CEM, MTA, and RCT). But, one year after treatment, there was a statistically different between vital pulp therapy (CEM and MTA) and root canal therapy ($P < 0.05$). Also, the results showed no statistical difference between CEM and MTA treatment in terms of TLR-2 and TLR-4 gene expression before and one year after treatment. TLRs are predominantly found in the innate immune system (cells involved in the first line of defense), including neutrophils and monocytes (macrophages and epithelial cells), which play an essential role in

identifying and killing microorganisms (19). Microarray DNA analysis has shown that expression levels of TLRs in gingival fibroblasts and periodontal ligaments increase in patients with periodontitis compared with healthy individuals (20). After stimulation of gingival fibroblasts with *P. gingivalis* lipopolysaccharide, the incidence of these factors increases. So far, 13 Toll-like receptors have been identified in humans (21, 22). Different members of the TLR family are responsible for identifying different types of PAMPs (Pathogen Associated Molecular Patterns) and assigning innate immune responses. For example, gram-negative bacteria can activate TLR-4 through their lipopolysaccharide, and gram-positive bacteria can activate TLR-2 through lipoteichoic acid (23). Therefore, considering the role of Toll-like receptors in the innate immune system as a factor in initiating the production and secretion of cytokines (24), the expression of TLR-2 and TLR-4 genes well indicates the performance of therapeutic methods in reducing inflammation and production and secretion of cytokines.

Acknowledgments

The authors are thankful to the higher authorities for the facilities provided.

Authors' contribution

This study was done by the authors named in this article, and the authors accept all liabilities resulting from claims which relate to this article and its contents.

Conflict interest

The authors declare that they have no conflict of interest.

Funding

A comparative study on the effect of different materials in the preservation of vital pulp of young permanent teeth. Item Number: 2020zc249

Availability of data and materials

The data used to support the findings of this study are available from the corresponding author upon request.

Statements and Declarations

The author declares that no conflict of interest is associated with this study.

References

- Cooper PR, Duncan HF, Widbiller M, Galler KM. Treatment of Immature Teeth with Pulp Necrosis. *Endod Mater Clin Pract* 2021; 47-79.
- Wikström A, Brundin M, Lopes M, El Sayed M, Tsilingaridis G. What is the best long-term treatment modality for immature permanent teeth with pulp necrosis and apical periodontitis? *Eur Arch Paediatr Dent* 2021; 22(3): 311-340.
- de-Jesus-Soares A, Prado MC, Nardello LC et al. Clinical and molecular microbiological evaluation of regenerative endodontic procedures in immature permanent teeth. *J Endod* 2020; 46(10): 1448-1454.
- Jiamiao Q, Xuening G, Liqiong M, Xiaoyan H, Song L. Clinical effects on reattachment and pulpotomy of young crown-fractured and pulp-exposed permanent incisors. *J Prevent Treat Stomatol Dis* 2018; 26(5): 309.
- Lu J, Yang X, Zhao W, Lin J. Effect Analysis of a Virtual Simulation Experimental Platform in Teaching Pulpotomy. *BMC Medical educ* 2021; 1-15.
- Cushley S, Duncan HF, Lappin MJ et al. Pulpotomy for mature carious teeth with symptoms of irreversible pulpitis: a systematic review. *J Dent* 2019; 88: 103158.
- Elmsmari F, Ruiz X-F, Miró Q, Feijoo-Pato N, Durán-Sindreu F, Olivieri JG. Outcome of partial pulpotomy in cariously exposed posterior permanent teeth: a systematic review and meta-analysis. *J Endod* 2019; 45(11): 1296-1306. e1293.
- Taha NA, Abdulkhader SZ. Full pulpotomy with biodentine in symptomatic young permanent teeth with carious exposure. *J Endod* 2018; 44(6): 932-937.
- Lin LM, Ricucci D, Saoud TM, Sigurdsson A, Kahler B. Vital pulp therapy of mature permanent teeth with irreversible pulpitis from the perspective of pulp biology. *Aust Endod J* 2020; 46(1): 154-166.
- Da Rosa W, Piva E, Da Silva A. Disclosing the physiology of pulp tissue for vital pulp therapy. *Int Endod J* 2018; 51(8): 829-846.
- Asami J, Shimizu T. Structural and functional understanding of the toll-like receptors. *Protein Sci* 2021; 30(4): 761-772.
- Hazard M, Wicker C, Qian F, Williamson A, Teixeira F. Accuracy of cold sensibility testing on teeth with full-coverage restorations: a clinical study. *Int Endod J* 2021; 54(7): 1008-1015.
- Zanini M, Hennequin M, Cousson P. Which procedures and materials could be applied for full pulpotomy in permanent mature teeth? A systematic review. *Acta Odontol Scand* 2019; 77(7): 541-551.
- Sooratgar A, Ahmadi Z, Asadi Y, Dibaji F, Shamshiri AR, Afkhami F. Evaluation of secondary thermal hyperalgesia resulting from pulpal inflammation in patients with symptomatic irreversible pulpitis. *J Endod* 2021; 47(6): 902-905.
- Chen Y, Chen X, Zhang Y et al. Materials for pulpotomy in immature permanent teeth: a systematic review and meta-analysis. *BMC Oral Health* 2019; 19(1): 1-9.
- Chen Y, Chen X, Zou X, Chen S, Zou J, Wang Y. Efficacy of low-level laser therapy in pain management after root canal treatment or retreatment: a systematic review. *Lasers Med Sci* 2019; 34(7): 1305-1316.
- Alqanass S. Quality of Root Canal Therapy (RCT) performed by the undergraduate students at the Qassim University, Kingdom of Saudi Arabia (KSA). *Med form* 2018; 29(6): 80-84.
- Careddu R, Duncan HF. A prospective clinical study investigating the effectiveness of partial pulpotomy after relating preoperative symptoms to a new and established classification of pulpitis. *Int Endod J* 2021; 54(12): 2156-2172.
- Andrukhov O. Toll-like receptors and dental mesenchymal stromal cells. *Front Oral Health* 2021; 2: 16.
- Sallustio F, Curci C, Stasi A, De Palma G, Divella C, Gramignoli R, Castellano G, Gallone A, Gesualdo L. Role of Toll-Like Receptors in Actuating Stem/Progenitor Cell Repair Mechanisms: Different Functions in Different Cells. *Stem Cells Int* 2019; 2019:6795845.
- de Barros Silva PG, Ferreira Jr AEC, de Oliveira CC et al. Chronic treatment with zoledronic acid alters the expression levels of inflammatory, bone, and apoptotic markers and Toll-like receptors 2 and 4 in rat dental pulp. *Oral Surg Oral Med Oral Pathol Oral Radiol* 2019; 128(2): 139-145.
- Guo X, Yin B, Wang C, Huo H, Azizaram Z. Risk assessment of gastric cancer in the presence of *Helicobacter pylori* cagA and hopQII genes. *Cell Mol Biol* 2021; 67(4): 299-305.
- Fernández A, Cárdenas A, Astorga J et al. Expression of Toll-like receptors 2 and 4 and its association with matrix metalloproteinases in symptomatic and asymptomatic apical periodontitis. *Clin Oral Invest* 2019; 23(12): 4205-4212.
- Jia L, Han N, Du J, Guo L, Luo Z, Liu Y. Pathogenesis of important virulence factors of *Porphyromonas gingivalis* via toll-like receptors. *Front Cell Infect Microbiol* 2019; 9: 262.