

Recombinant Plasminogen Activator Modified Nanoparticles for Targeting Thrombolysis in Branch Retinal Vein Occlusion

Hepeng Zhang, Shasha Han, Lan Zhang, Yanfang Guo, Yuefeng Li*

Department of Ophthalmology, Hengshui People's Hospital (Harrison International Peace Hospital), Hengshui, 053000, China

ARTICLE INFO

Original paper

Article history:

Received: October 14, 2021

Accepted: March 19, 2022

Published: March 31, 2022

Keywords:

Antithrombotic Drugs, Branch Retinal Vein Occlusion, Targeted Drug Delivery, Recombinant Plasminogen Activator, Nanomedicine

ABSTRACT

Branch Retinal Vein Occlusion (BRVO) is the second chronic branch retinal vascular disease that causes abnormal vision loss after acute branch retinal disease in type 2 diabetes. There is no scientific conclusion about its specific pathogenic mechanism at present. Most clinical scholars generally support the theory that the partial human anatomical structure and various systemic risk psychological factors cause insufficient oxygen supply and hemostasis in the local branch retinal arteries. The research results of this article aim to reconstruct a non-nanocell-targeted thrombolytic drug delivery system without modification of rtPA without polyethylene glycol-methyl polycaprolactone and to re-evaluate its thrombus targeting and dissolution. The effect and safety of thrombus provide a new strategy for realizing combined treatment of thrombus. It is a study on the targeting of rtPA-NP to thrombus and its thrombolytic properties. HPLC method was used to detect the binding of fibrin clot prepared in vitro with coumarin-6 labeled NP and rtPA-NP; immunofluorescence technique was used to observe the location of nanomedicine and fibrin clot in branch retinal vein occlusion model Condition. The rtPA-NP drug delivery system constructed in this study not only retains the activity of rtPA and good thrombus targeting but also significantly prolongs its half-life and simplifies the way of administration. The therapeutic efficiency of rtPA-NP thrombus targeted administration on branch retinal vein occlusion reached 85.64%. The successful construction of the rtPA-NP thrombus targeted drug delivery system provides a new way for thrombosis treatment and lays the foundation for the future combination of anticoagulants and vascular protection drugs to achieve the combined treatment of thrombosis and the development of safe and efficient thrombolytic drugs.

DOI:<http://dx.doi.org/10.14715/cmb/2022.68.3.23> Copyright: © 2022 by the C.M.B. Association. All rights reserved.



Introduction

Vein vascular occlusion disease on the retina is the second most common acute retinal venous vascular occlusion disease. According to the statistical analysis of the basic population over 30 years old in the United States, Europe, Asia and Australia, the incidence of branch retinal vein occlusion is 0.442%. Retinal neovascular occlusion disease leads to a significant decrease in children's vision. The main causes include macular edema, omental ischemia in the macular area, and the formation of neo-omental hemangioma in both eyes. Among them, the edema of the macular area in both eyes is a cause of the obvious decline in children's vision. The main cause is macular edema in 5-15% of BRVO (1,2).

At present, the treatment of retinal vein occlusion is very limited. Continuous intravenous infusion of tissue-type plasminogen activator (rtPA) is currently the only FDA-approved treatment method. Even so,

the use of rtPA is limited to 3 symptoms. Within hours, there is also the risk of concurrent branch retinal vein hemorrhage, especially for patients who exceed this treatment time window, the risk of branch retinal vein hemorrhage will increase significantly, which severely limits the application of rtPA. Clinically, less than 5% of patients with retinal vein occlusion can benefit from rtPA treatment. In addition, rtPA thrombolytic combination therapy is only effective for some patients with thrombolysis. After the blood vessel is unblocked again, it still has a high reinfarction rate of branch retinal veins. Therefore, the thrombolytic treatment of active retinal venous catheter occlusion currently urgently needs to continuously improve the efficacy and safety of rtPA thrombolytic treatment (2,3).

At present, the main clinical research results based on the rtPA-related treatment of acute retinal and arteriovenous catheter occlusion-related diseases are:

*Corresponding author. E-mail: lubei3121653221@163.com
Cellular and Molecular Biology, 2022, 68(3): 202-212

Huang F's acute retinal vein branch arteriovenous catheters with 3 cases (3 incision eyes) patients with an average visual acuity of fewer than 0.1 Patients with obstructive diseases underwent glass-eye prosthesis and binocular arteriovenous catheterization with flat binocular parts. The results of the examination showed that the vitreous body of the 3 patients after the incision was clear, the visual acuity was uniform and the degree of improvement was obvious in different periods, the micro hemorrhage in the retina and the edema of the macula were significantly reduced, and no postoperative complications may occur, but this method The treatment of this disease is not thorough (1). Na studied the relationship between hemorheology in the carotid artery and the clinical onset and prognosis of other retinal and jugular vascular occlusions and found that the hemorheology in the carotid artery was related to other retinal and jugular vascular occlusions There may be a greater correlation between the clinical onset and prognosis of the disease. The hemorheological abnormalities in the carotid omental artery should be detected as soon as possible to prevent or greatly reduce the risk of other diseases related to retinal and jugular vein vascular occlusion. The method is risky to a certain extent (2). Min SK observed the clinical efficacy of taking XuefuZhuyu Decoction for the treatment of acute subretinal venous vascular occlusion and found that taking XuefuZhuyu Decoction for the early treatment of acute subretinal venous vascular occlusion had a significant clinical effect (3). Deb AK explored the direct relationship between the four items of blood hyperlipidemia and long-term blood coagulation and bleeding and the clinical diagnosis of the four items of clinical patients with long-term retinal and ocular arteriovenous retinal obstruction. Hyperlipidemia and blood hypercoagulability are both clinically the four clinical diagnoses of long-term RVO in patients that can also play a certain immunosuppressive treatment at the same time. For clinical patients who have long-term blood hyperlipidemia and hypercoagulability, they should be treated in time after the clinical onset of RVO. Clinical symptomatic treatment and intervention were carried out to correct the four adverse states of hyperlipidemia and blood coagulation, but the study only played a preventive effect on the disease (4). Costa JV discusses the early

rate of acute radiation laser surgery in patients eyes and clinical treatment application research effects for acute macular venous valve vascular occlusion on the retina. Laser treatment can also be used for acute macular venous valve vascular occlusion It has a good clinical treatment rate and early clinical application research value; radiation laser treatment can greatly improve its early clinical application rate and curative effect; laser can directly promote the acute macular venous vascular occlusion of the patient's ocular cortex thickness in the central omental depression reduce, and there are few adverse reactions, but this therapy is too expensive to be widely used (5).

The research results of this article are intended to be used to construct a rtPA mutually modified drug delivery system using polyethylene glycol-ester on polycaprolactone nano as a targeted thrombolytic agent, and to evaluate its thrombus targeting, the thrombolytic effect and safety provide a new strategy for the realization of thrombosis combined therapy. The polyethylene glycol-poly lactide nanoparticles (NP) were prepared by a single emulsification method, and the EDC/NHS method formed a covalent connection with rtPA to prepare rtPA-NP. The particle size, particle size distribution width and surface film potential of nanoparticles were detected by the dynamic light scattering method. Through the combination of Chinese and Western medical methods, namely Western medicine acupuncture and puncture, Chinese medicine "QujiTongluo Recipe" and combined treatment of Western medicine "Anti-vascular endothelial growth factor drugs", treatment of acute retinal duct branch and optic vein duct occlusion (Bravo Retinal Vein Occlusion, BRVO) As well as the analysis of the early clinical efficacy data of secondary macular edema (Macular Edema, ME), we found the clinical superiority and efficacy of the combination of Chinese and Western medicine in the treatment of the disease and in-depth exploration of its multiple possible pharmacological response mechanisms.

Principle and Overview

The Mechanism of Action of Recombinant Plasminogen Activator

The key to the treatment of branch retinal vein occlusion is to achieve vascular recanalization as soon as possible. Tissue-type three-dimensional

plasminogen protein activation inhibitor (rtPA) is currently the only thrombolytic therapy approved by the European and American FDA countries. Compared with other plasminogen drug therapies, it has targeted, plasminogen protease. The obvious advantage of higher safety, but there may also be some inevitable application limitations: the half-life of thrombolysis is short, only 2-5 minutes; the clinical use of rtPA is limited to the first 3 hours of thrombolytic symptoms. At the same time, there may be serious complications and the risk of blood vessel bleeding under the branch of the retinal vein; rtPA thrombolytic biotherapy is only effective for some patients with thrombolysis. After the blood vessels are unblocked again, the occlusion of the branch of the retinal vein may still recur again (6-7). Therefore, there is an urgent need for the thrombolytic treatment institutions of retinal vein branch submembrane vein vascular occlusion to continuously improve its rtPA thrombolytic biological resource utilization, thrombolytic therapy effect and drug safety. The charging status of rtPA is shown in Table 1:

Table 1. The particle size and Zeta potential of NP and rtPA-NP (n=3).

Nanoparticles	Mean Size (mean±SD, nm)	Zeta potential (mV) ^a
NP	80.15±4.1	-7.45±1.85
rtPA-NP	125.0±2.5	-8.59±1.57

The summary of the overall construction solution of the complete nano-ring-opening drug delivery system is as follows: First, the block ring-opening drug-delivery polymerization method is used to separately cap the methoxy lactone-terminated ring-opening polyethylene glycol (MPEG) or the carboxyl lactone-terminated ring-opening Polyethylene glycol (COOH-PEG) reacts with ϵ -caprolactone to synthesize a block drug delivery copolymer containing PEG-PCL diol (8-9). The above-mentioned block copolymers are mixed in a certain amount of ratio, and complete nanometer particles are made by a single polymerization emulsification/solvent polymerization evaporation method; then each nanometer drug delivery particle is made by the polymerization method using EDC/NHS. Its surface carboxyl group (COOH) is activated, and rtPA emulsification reaction merges to form a covalent bond connection to obtain tissue-type plasmin activator-modified nanoparticles (rtPA-NP). The specific operation steps are shown in Figure 1.

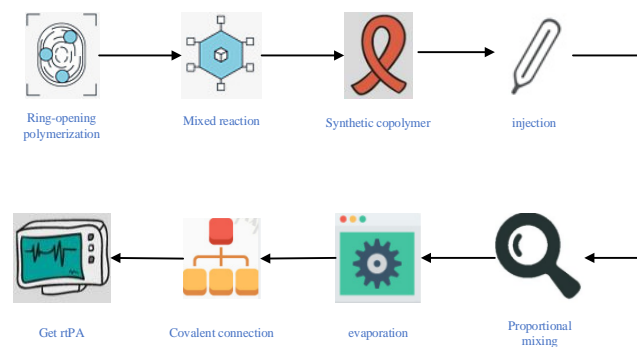


Figure 1. Operation steps of obtaining tissue-type plasmin activator-modified nanoparticles

This experiment uses a single emulsification/solvent evaporation method to prepare nanoparticles. The prepared nanoparticles can easily encapsulate fat-soluble fluorescent materials, such as coumarin-6, far-infrared probe-Dir; if the nanoparticles are used Prepared by the double emulsion method, the inner water phase of the nanoparticle core is suitable for encapsulating various hydrophilic drugs, such as water-soluble genetic drugs or protein and peptide drugs. Because the hydrophilicity of PEG determines that the surface of the nanoparticle is covered by it, if a certain amount of carboxyl-modified PEG is added, it can easily react with the amino group of the protein to form a covalent bond, and it can be easily connected to the target protein. Therefore, the nano-drug loading system has the advantages of convenient drug loading and convenient realization of multi-functions, which is the current research hotspot of pharmaceuticals(10-11).

Pathology of Retinal Vein Occlusion

Retinal vein occlusion (RVO) has been ranked second among all influencing factors of central retinal vein branch vascular disease and its pathogenesis and blindness. It is second only to other retinal venous vascular diseases with acute diabetic characteristics (12-13). Central vein branch occlusion can completely appear on both sides of the central retinal vein branch on both sides of the central vein (cRVO), but it can not only appear on both sides of the central retinal vein branch on both sides of the central vein (bRVO), based on the analysis of the early clinical symptoms of people over 30 years of age with early symptom-based myopia in the United States, Europe, Asia, and Australia. The morbidity rates are 0.442% and 0.08%, respectively. After the occurrence of venous

occlusion, the blood vessels of the fundus veins were congested and dilated, and the retina appeared edema and hemorrhage, as well as cotton wool spots, exudation and macular edema. Macular edema is the cause of the sharp decline in vision, and macular edema can occur in 5-15% of BRVO (14-15). Subretinal vein vascular obstructive macular edema can affect the quality of daily life of macular patients when it is severe. Researchers have found that the longer the onset of acute macular edema in both eyes, the greater the damage to the tissues that constitute the central depression and structure of the macular edema. Therefore, the prevention and treatment of acute subretinal vein vascular occlusion macular edema are very important. The number of people suffering from retinal vein occlusion in two certain areas over time is shown in Figure 2.

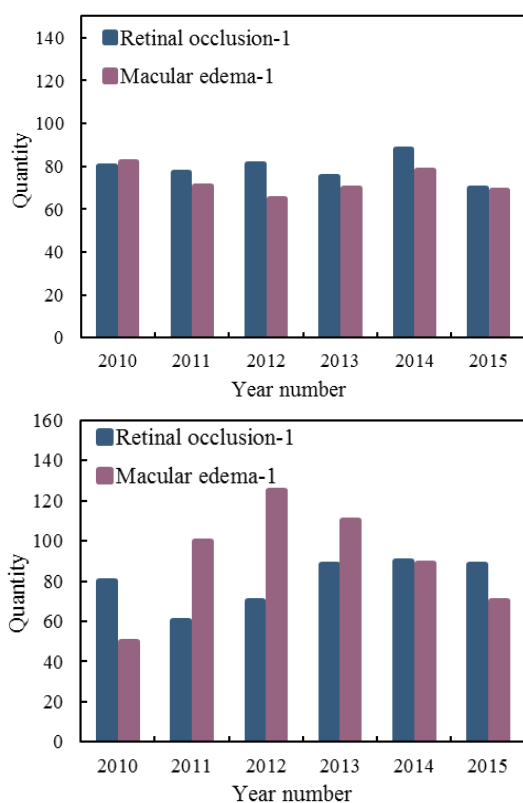


Figure 2. The number of confirmed patients with retinal vein occlusion in two hospitals over time

The main causes of vision loss caused by branch retinal vein occlusion include cystoid macular edema and vitreous hemorrhage caused by neovascularization. Many studies have confirmed that cystoid macular edema and neovascularization are closely related to retinal ischemia. Studies have found

that when the amount of oxygen is increased or the time of perfusion of the oxygen supply area is extended, the area of bloodless in the perfusion area gradually becomes smaller, and the formation of a new venous blood vessel is also sparse or even completely subsided. Therefore, bloodless perfusion of the macular area It is often recognized by clinical scholars that laser is an important diagnostic indicator for the treatment of retinal barrier ischemia. For example, when a retinal vein branch neovascular occlusion occurs in the eye with a bloodless perfusion macular area, the serum-soluble retinal vein barrier function is severely damaged, the blood oxygen factor content in the retina is significantly reduced, and the endothelial growth cell sodium The pump can continue to maintain the normal oxygen supply function, which leads to a significant increase in blood permeability of new blood vessels, serious blood leakage from blood vessels, and induces the formation of ocular neovascularization and macular ocular edema, which leads to a significant decrease in vision³. Triamcinolone acetonide laser, as a completely long-acting blood glucose corticosteroid, can effectively inhibit the autoimmunity of endothelial cells, stabilize the formation of a serum-soluble retinal vein barrier, and reduce edema in the macular area of the eye, but if a retinal barrier is bloodless perfusion If the area is not completely covered by laser treatment, the endothelial growth factor in the blood vessels will still be lost continuously. Clinically, it is often shown that the blood vessels have a rebound phenomenon due to laser treatment (16-17).

Selection of Nanoparticle Materials

At present, there are a variety of new polymeric nanomaterials and their product series that can provide users to choose from, such as: polylactic acid (PLA), deoxyacetylmethylene chitosan, polycyanoacrylate polysaccharide and its various polymer derivatives, A variety of polymerized copolymers of lactic acid-dodecahydroxy phenylacetic acid (PLGA), polylactic acid dicycloprolactone (PCL) and so on. From the perspective of various biochemical compatibility, biochemical degradability, and safety of this nanomaterial, PCL can be almost completely degraded in the body, and the products after degradation are mainly gaseous carbon dioxide and concentrated ammonia, which will not directly

interfere with the normal various physiological and chemical activities of human cells have three major advantages such as complete biochemical degradation and good biochemical compatibility. It is one of the raw materials of the U.S. Food and Drug Administration (FDA) nationally approved products that can be used in pharmaceuticals (18-19).

Because PCL rice grains are loose and hydrophilic solid materials, after directly adding water to prepare processed nanoparticles, they can be quickly and effectively blocked by the human liver, kidney, heart, spleen and blood after intravenous injection in the body, thereby being mononuclear in the body. The immune system of macrophage leukocytes quickly recognizes and phagocytoses them, and stays in the blood for a short half-life, making it difficult to get better use. Polyethylene glycol (peg) molecules have a good affinity for hydrophobicity. If a peg chain of a hydrophobic molecule is connected to its PCL chain, an amphiphilic dimer block-type copolymer is formed; through this in the nanoparticles prepared by a copolymer, the hydrophobic PCL is located inside the nanoparticles, and the hydrophilicity of PEG determines that it covers the surface of the nanoparticles. Due to the safety protection of the peg chain, nano-drug particles can almost completely escape the gene recognition and immune phagocytosis of the immune system of mononuclear macrophage receptor cells, thereby greatly extending the half-life of other nano-drug particles in anticoagulation. Improve the blood circulation time of the nanomedicine. Therefore, this topic chooses PEG-PCL block copolymer as the nanoparticle material. Synthetase method: use the method of ring-opening lactone polymerization to separately polymerize the components into COOH-PEG-PCL and synthesize MPEG-PCL: place an appropriate amount of MPEG or COOH-PEG and ϵ -caprolactone solution in a dry circle In a flat-bottomed combustion flask, add the appropriate amount of the chemical catalyst octanoic acid and stannous lactone solution. The reactants are quickly stirred at 70°C under rapid decompression and placed in a vacuum flask for 1h, and then reacted at 160°C for 4h. After the solution was cooled, the product was dissolved with tetrahydrodichloromethane (ch₂cl₂) test solution, and then precipitated with heat or excess ether-dihydro petroleum or ether and its mixture solution. The

product precipitate was dissolved with the test solution, then precipitated with heat or excess methanol solution, and dried under vacuum at 40°C for 24 h. Calculate the average molecular weight of COOH-PEG-PCL and MPEG-PCL. The calculation method is as follows:

$$M_n(NMR) = \frac{M_n(PEG)*72*4}{44*3} [1]$$

For macromolecular structure:

$$O(k) = \sum_j w_j^0 X_j(k) [2]$$

$$X_j(k) = f(S_j(k)) [3]$$

$$S_j(k) = w_j^d X_j(k-1) + \sum_i w_{ij}^l I_i(k) [4]$$

$$f(x) = \frac{1-e^{-x}}{1+e^{-x}} [5]$$

According to the elemental composition of the nanoparticles, we can get:

$$P_j(k) = \frac{\partial X_j}{\partial w_j^d} = f(S_j) X_j(k-1) [6]$$

$$M(k) = \frac{\partial X_i}{\partial w_{ij}^l} = f(S_j) I_i(k) [7]$$

Considering that the nanomedicine must be covalently connected with rtPA, the carboxyl-terminated polyethylene glycol (COOH-PEG3400) with a molecular weight of 3400 Daltons (D) and a monomethoxy group with a molecular weight of 3000 D was selected for this project. End polyethylene glycol (MPEG3000). Since the COOH-PEG3400 chain is longer than the MPEG3000 chain, rtPA is connected to the carboxyl group and protrudes from the surface of the nanoparticle. This design is very conducive to rtPA's targeted thrombolytic effect(20-21).

Materials and methods

Instruments and Materials

The equipment is shown in Table 2:

Table 2. Instrument and equipment list

Equipment name	Origin
Electronic balance	Sartorius, BSA124S-CW, Germany
Rotary evaporator	Shanghai Yongting, RE-5203, China
Constant temperature water bath	Guowang, HH-1, China
Vortex oscillator	Scientific Industries, S1-0246, USA
Constant temperature magnetic stirrer	QilinEier, GL-3205B, China
Desktop small centrifuge	Eppendorf, 5418, Germany

Materials and reagents are shown in Table 3:

Table 3. Materials and reagents

Drug name	Origin
ϵ -caprolactone	Purity>99.9%, Sigma, USA
Monomethoxy-terminated polyethylene glycol	Purity>99.8%, Jiankai, China
Carboxyl-terminated polyethylene glycol	Purity>99.8%, Jiankai, China
Trichloromethane	Analytical Pure, Sinopharm Group, China
Sodium Cholate	Purity>99.9%, Sigma, USA

The main solutions in this study are shown in Table 4:

Table 4. Solution preparation

Solution name	Configuration method
0.6% sodium cholate	Stir magnetically to dissolve
0.01M PBS buffer	Add pure water to 900ml, adjust pH to 7.4, and dilute to 1L
0.1M MES buffer	Add water to 190ml, adjust pH to 6.0, and dilute to 200ml

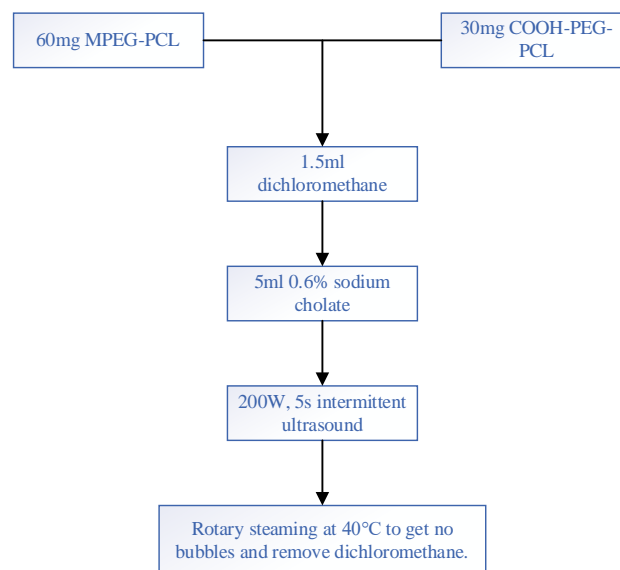
Preparation of Recombinant Plasminogen Activator Modified Nanoparticles

As early as the 1980s, rtPA was approved for the treatment of branch retinal vein occlusion and was subsequently approved for the treatment of ischemic branch retinal vein stroke (22). Until now, it is the only drug approved by the FDA for the treatment of ischemic branch retinal vein occlusion. This is due to the advantages of RtPA's targeted thrombolytic properties, namely:

- 1) High affinity to fibrin, with an affinity constant of $0.16\mu\text{M}$;
- 2) When rtPA is combined with fibrin, its ability to activate plasminogen will increase 1000 times, resulting in specifically targeted thrombolysis, and at the same time, it has little interference with the blood coagulation system.

RtPA is a recombinant protein composed of 527 amino acids and expressed through genetic engineering. It is synthesized by cloning human tissue-type plasminogen activator cDNA from a human melanoma cell line, integrating it into Chinese hamster ovary cell genes, expressing and secreting it into the cell culture supernatant and purifying it. Its physiological properties are indistinguishable from physiological plasminogen activators.

Mix MPEG-PCL and COOH-PEG-PCL in a ratio of 2:1 (W/W), and prepare NP by a single emulsification/solvent evaporation method. The main steps are shown in Figure 3.

**Figure 3.** The structure diagram of the operation flow for preparing NP

The main steps for the determination of NP concentration are as follows:

- 1) Put 1ml of the obtained NP solution into a weighed EP tube, bake in an oven at 60°C for 48h to constant weight, and weigh.
- 2) Take 200ul of NP solution and measure the absorption spectrum of PEG-PCL nanoparticles by an ultraviolet spectrophotometer to determine its
- 3) The highest absorption peak, and the wavelength of light. It is determined that the wavelength of the highest absorption peak light of the nanoparticles is 650nm.
- 4) Take 1ml of NP solution for comparative dilution: 1:1, 1:2, 1:4, 1:8, 1:16, 1:32, respectively measure 650nm wave
- 5) The absorbance of the NP solution is long.
- 6) Make a standard curve to obtain a standard curve of nanoparticle concentration.
- 7) Dilute the concentration of nanoparticles to 25mg/ml.

RtPA-NP was placed at 4°C for a week, and the activity of rtPA was detected at different time points (1, 3, 5, and 7 days). Compared with the activity of free rtPA, there is no decrease in activity. This confirms that rtPA-NP has sufficient stability and can be stored at 4°C for a week, and its activity is shown in Figure 4:

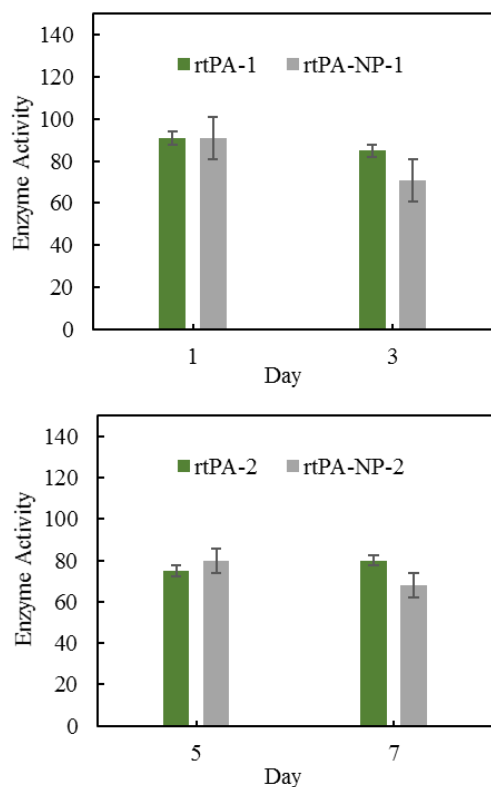


Figure 4. The remaining enzyme activity of free rtPA and rtPA conjugated to NP after incubation at 4°C. No significant differences were found between the rtPA-NP and rtPA group (n=4, p>0.05)

Establishment of Mouse Model

In order to explore whether rtPA-NP has an affinity for branch retinal vein occlusion, we prepared an *in vitro* fibrin thrombus based on references. The main steps are:

1) The rats were deeply anesthetized by intraperitoneal injection of 1g/kg of 10% chloral hydrate.

2) After the rat is fixed, the abdominal cavity is opened, the contents of the abdominal cavity are opened, the abdominal aorta is exposed, and the proximal end of the abdominal aorta is carefully separated and clamped.

3) Take a 20ml syringe moistened with 3.8% sodium citrate, insert the needle into the distal end of the abdominal aorta, loosen the arterial clamp, and draw blood from the abdominal aorta.

4) Mix 9 parts of abdominal aortic blood with 1 part of 3.8% sodium citrate, centrifuge at 2000g for 5 minutes, and collect plasma.

5) Centrifuge the plasma again at 2000g to remove platelets and residual blood cells.

6) Take 400ul plasma and add 8ul 1M CaCl₂ solution, mix well, and let it stand for a few minutes to form a fibrin thrombus clot.

7) Wash the fibrin thrombus several times with PBS.

There are many new models of bilateral venous thromboembolism occlusion method of retinal vein branches, photochemical method, thread thrombosis method, and bilateral venous thrombosis occlusion method of retinal vein branches. One of the photochemical methods is simple to operate. Although this method can quickly form venous thrombosis, its natural pathological mechanism is completely inconsistent with the specific natural development of the above-mentioned retinal vein branch bilateral venous thrombosis. Currently, it is rarely widely used. The branch retinal vein venous thromboembolism method is widely used in the clinical research of thrombolytic drugs, but the actual operation process is difficult, the conditions and technical requirements are relatively high, and it is difficult to carry out independently. Since the linear thrombolysis thrombosis model is easier to develop independently, the thrombosis model found that after the aortic blood vessel in the retinal vein branch thrombosis is blocked, secondary thrombosis may occur in the small blood vessels downstream, and a large number of thrombi may be formed. The area of retinal vein branch thrombosis venous blood vessel occlusion thrombosis is relatively fixed. It is currently the most widely used and used thrombosis model of retinal vein branch vascular venous thrombosis in clinical research. Therefore, we chose the thread embolization model and follow the method of reference. The main steps are as follows:

1) The rats were anesthetized with chloral hydrate at 0.5 g/kg body weight and fixed on the operating table.

2) Carefully cut off the rat hair on the front of the neck and disinfect with iodophor.

3) Cut the skin in the middle of the neck and separate the subcutaneous tissue with surgical forceps. After separating the anterior trachea muscle, separate downward along the right sternocleidomastoid tendon until the carotid sheath is pulled upwards to separate the carotid sheath and fully expose the neck Common artery.

4) Continue to separate the common carotid artery, external carotid artery, and internal carotid artery upward, and ligate the distal end of the external carotid artery.

5) Clamp the proximal end of the common carotid artery and the distal end of the internal carotid artery with an arterial clip, cut a small opening at the proximal end of the external carotid artery with ophthalmological scissors, insert a tethered thread, and pass through the external carotid artery to the common carotid artery to reach the internal carotid artery, Continue to advance for about 18mm, and stop inserting when there is a sense of resistance, indicating that the head of the tether has reached the mouth of the middle artery (MCA) of the branch retinal vein, and the tether is ligated.

6) Close the wound, suture the skin and disinfect the skin with an alcohol cotton ball.

7) Block the blood flow of the branch retinal vein and middle artery (MCAO) for 90 minutes, and remove the thrombus.

Results and discussion

Model Evaluation

This topic uses the thread plug method to prepare the branch retinal vein occlusion model, as shown in the figure: the thread is inserted from the external carotid artery and reaches the vicinity of the middle artery of the branch retinal vein, blocking the blood flow of the middle artery of the branch retinal vein and the downstream blood supply, and it is removed after 90 minutes. After threading, 120 minutes later, slices of branch retinal veins were taken for fibrin staining. The results showed that there were cord-like microthrombi composed of fibrin downstream of the middle artery of the branch retinal veins. This indicates that the model is successfully prepared and can be used to evaluate the targeting and thrombolytic properties of rtPA-NP.

In order to avoid interference with the results, this experiment first inactivated plasminogen with the prepared fibrin thrombus in a 56°C water bath for 5 minutes and discussed the binding of rtPA-NP to fibrin. After incubating the fibrin thrombus with rtPA-NP or NP with coumarin-6 as a tracer, we found that the fluorescence intensity of the thrombus after incubation with rtPA-NP was significantly stronger than that of the NP group. This positively confirms

that rtPA-NP has an affinity for fibrin thrombus. In order to prove from the negative that rtPA-NP is a specific binding to fibrin thrombus, we designed an experiment with excess rtPA and fibrin thrombus after incubation, and then with rtPA-NP. Figure 5 shows that the binding of rtPA-NP to fibrin is significantly reduced ($n=4$, $p<0.05$). These results fully confirmed the targeting of rtPA-NP to fibrin thrombus.

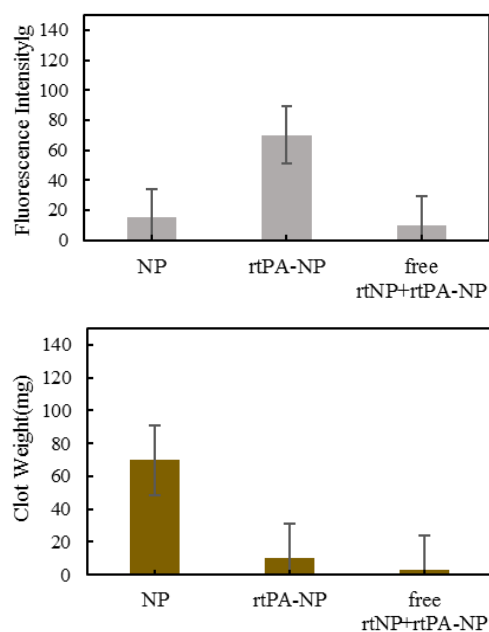


Figure 5. The binding affinity of rtPA-NP for fibrin in vitro

According to the results of this part, the branch retinal vein occlusion model rat branch retinal vein ischemia for 2h, microthrombus formed in the branch retinal vein, also confirmed the existence of fibrin thrombus. After 30 minutes of injection of coumarin-6-labeled rtPA-NP or NP into the tail vein, fibrin staining was performed on the dead area of the branch retinal vein and observation with a fluorescence microscope. The results showed that there was no obvious green fluorescence in the thrombotic lesions in the NP group (Coumarin-6) distribution, while the thrombus lesions in the rtPA-NP group showed green fluorescence along with the fibrin thrombus. The superposition further shows that rtPA-NP and fibrin have the same localization. This proves that rtPA-NP has the ability to specifically target branch retinal vein occlusion.

After rtPA is attached to the surface of the nanoparticle, the use of rtPA's specific affinity for fibrin to give the rtPA-NP drug delivery system

thrombus targeting function is the core of this topic. Using coumarin-6 as a fluorescent probe and blank nanoparticles as a control, we designed an in vitro thrombus targeting experiment. The results showed that the binding of fibrin thrombus in the rtPA-NP group was significantly stronger than that in the NP group, and this binding ability could be inhibited by excessive free rtPA. This shows that rtPA-NP specifically binds to fibrin, and rtPA linked to nanoparticles retains the targeting of rtPA to fibrin. Furthermore, we confirmed through in vivo experiments that rtPA-NP can specifically target the branch retinal vein occlusion, while the control group NP group has no such effect. This is consistent with the results of in vitro experiments, and from another point of view, it is confirmed that rtPA-NP retains the targeting of rtPA to fibrin. Each RtPA-NP particle is connected with multiple rtPA molecules. Theoretically speaking, the targeted overlap of multiple rtPA on thrombus can enhance the effect of rtPA-NP thrombus targeting, but this experiment cannot be used to obtain rtPA- The conclusion that NP is more targeted than rtPA. The thrombus targeting properties of rtPA-NP are clarified. We can further use the thrombus targeting properties of the RtPA-NP drug delivery system in subsequent studies to combine various anti-thrombotic drugs to achieve combined treatment of thrombosis and achieve both improvements The thrombolytic effect can reduce the dosage and the purpose of reducing the risk of bleeding.

As a fibrinolytic drug, RtPA will affect the coagulation system to a certain extent. Therefore, we explored the effect of rtPA-NP on the coagulation system. Detection of coagulation indicators after 2 hours of administration: prothrombin time (PT), activated partial prothrombin time (APTT), fibrinogen (Fbg), fibrin-specific degradation products (D-dimer), results showed that the PT, APTT, and Fbg of the experimental group rtPA-NP group were not significantly different from the normal saline control group, but D-dimer was significantly higher than the normal saline group and the free rtPA tail vein injection group, and the difference was significant ($n=4$, $p<0.001$). It can be proved that rtPA-NP has no effect on the coagulation system when the dose is 20mg/kg, and it further proves that rtPA-NP specifically degrades the main component of

thrombus-fibrin, leading to D-dimer The increase in serotonin has played a thrombolytic effect in the body. After 90 minutes of injection of normal saline, rtPA-NP and free rtPA into the tail vein of model rats, the coagulation index was detected. The D-dimer content in circulating blood increases significantly, which indicates that rtPA-NP specifically, degrades fibrin. Combining targeted experiments and thrombolytic experiments, we can infer that rtPA-NP exerts thrombolytic activity in the body, and specifically dissolves the main component of thrombosis-fibrin; at the same time, rtPA-NP has no obvious effect on the coagulation system It has better safety.

By preparing a rat branch retinal vein occlusion model, the rats were given normal saline, free rtPA, and rtPA-NP via tail vein injection. After 24 hours, the degree of nerve damage and the dead area of the branch retinal vein occlusion were evaluated. The results showed: rtPA-NP intravenous injection group the degree of nerve damage and the dead area of branch retinal vein occlusion were significantly reduced compared with the free rtPA intravenous injection group ($p<0.001$), which was consistent with the results of in vitro experiments. This shows that rtPA-NP exerts thrombolytic activity, improves the blood supply of the branch retinal vein, and saves the dying branch retinal vein tissue; at the same time, the role of thrombo-targeting properties will also lead to more specific thrombolysis. The administered dose of RtPA-NP (rtPA 1mg/kg) is only 10% of the conventional intravenous infusion dose of rtPA (10mg/kg for rats), which can exert a thrombolytic effect and has a good therapeutic effect on branch retinal vein occlusion. The cure rate can reach 85.64%. This is due to the prolonged half-life of rtPA-NP and the thrombus targeting of rtPA-NP. Overall, this investigation showed a new aspect of modified therapeutic nanomaterials (23-25) for targeting thrombolysis in branch retinal vein occlusion.

Conclusions

In this paper, an in vitro thrombosis model and an in vivo branch retinal vein occlusion model were prepared, and the thrombo-targeting and thrombolytic properties of rtPA-NP were studied, and the safety of rtPA-NP was preliminarily evaluated. These research results fully confirm that rtPA-np rats have obvious targeted thrombolytic therapy effects, and the dose of

rtPA-np given is only 10% of the dose of a single routine thrombolytic intravenous infusion of rtPA-p rats, that is, it can give full play to the effect of thrombolytic therapy, and thrombolysis has no obvious effect on the function of the blood coagulation vascular system. In summary, RVO thrombosis is one of the most common diseases in ophthalmology at present, and its clinical pathogenesis involves many influencing factors. The current clinical treatment methods for ophthalmic RVO include various clinical diagnosis and treatment methods such as external drug injection therapy, surgical external drug combination therapy, injection external drug combination therapy, and laser therapy. Laser injection of drugs directly was done on the upper part of the eye and the upper half of the branch of the retinal vein. Laser or film injection surgery for injection drug treatment, glass injection in the ocular lens cavity for laser injection drug treatment, external drugs and other new types of drugs The therapeutic methods of drugs have brought a new concept of clinical treatment methods to the early clinical diagnosis and treatment and application fields of ocular and branch retinal vein branch thrombosis bilateral blood vessel vein branch thrombosis, but different types of ophthalmology clinics The clinical pathogenesis and clinical application effects of various thrombosis treatment methods and their clinical focus are different. It is expected that there is still a lot of room for future treatment and it may further improve its ophthalmological treatment. See omental branch veins and branches. Early clinical diagnosis and treatment of thrombosis, bilateral vascular venous branch thrombosis, vascular obstruction and other related clinical complications, and the level of applied technology.

Acknowledgments

Not applicable.

Interest conflict

The authors declare that they have no conflict of interest.

References

1. Huang F, Tan T, Dashtbozorg B, et al. From local to global: a graph framework for retinal artery/vein

- classification. *IEEE Trans NanoBioscience*, 2020;(99):1-1.
2. Na, Eun, Lee, et al. Sectoral changes of the peripapillary choroidal thickness in patients with unilateral branch retinal vein occlusion. *International J Ophthalmol* 2019; 12(03):126-133.
 3. Min S K, Lee S M, Han J K . Characteristics of Optical Coherence Tomography Angiography Findings in Chronic Inactive Branch Retinal Vein Occlusion. *J Korean Ophthalmol Society* 2021; 62(6):777-785.
 4. Deb A K, Deb A K, Rathinam N, et al. Bilateral vitreous hemorrhage with branch retinal vein occlusion secondary to hyperhomocysteinemia: A rare case report. *Kerala J Ophthalmol* 2021; 33(2):194-196.
 5. Costa J V, Moura-Coelho N, Abreu A C, et al. Macular edema secondary to retinal vein occlusion in a real-life setting: a multicenter, nationwide, 3-year follow-up study. *GraefesArch Clin Exp Ophthalmol* 2021; 259(2):343-350.
 6. Kumar A, Yadav R, Kumar R, et al. To study early and late effect of intravitreal injection Ranibizumab on Cystoid Macular Edema(CME) due to Branch Retinal Vein Occlusion (BRVO). *Indian J Clin Exp Ophthalmol* 2021; 7(1):194-198.
 7. Y An, Park S P, Kim Y K . Aqueous humor inflammatory cytokine levels and choroidal thickness in patients with macular edema associated with branch retinal vein occlusion. *Int Ophthalmol* 2021; 41(7):2433-2444.
 8. Arslan G D, Guven D, Demir M, et al. Microvascular and functional changes according to the fundus location of the affected arteriovenous crossing in patients with branch retinal vein occlusion. *India J Ophthalmol* 2021; 69(5):1189-1196.
 9. Xu S, Wang L, Kong K, et al. Metamorphopsia and Morphological Changes in the Macula after Scleral Buckling Surgery for Macula-Off Rhegmatogenous Retinal Detachment. *J Ophthalmol* 2021; 2021(10):1-7.
 10. Rosenblatt T R, Vail D, Saroj N, et al. Increasing Incidence and Prevalence of Common Retinal Diseases in Retina Practices Across the United States. *Ophthalmic Surg Lasers Imaging Retina* 2021; 52(1):29-36.
 11. Al-MoujahedA, Vail D, Do D V . Racial Differences in Anti-VEGF Intravitreal Injections Among Commercially Insured Beneficiaries. *Ophthalmic Surg Lasers Imaging Retina* 2021; 52(4):208-217.
 12. Pan L, Cho K S, Yi I, et al. Baicalein, Baicalin, and Wogonin: Protective Effects against Ischemia-Induced Neurodegeneration in the Brain and Retina. *Oxid Med Cell Longev* 2021; 2021(5):1-16.
 13. MahendradasP, Sethu S, Sanjay S, et al. Retinal vein occlusion in COVID-19: A novel entity. *India J Ophthalmol* 2021; 1(69):194-195.
 14. Yong M L, Min W L, Yong Y S, et al. Repeatability of Optical Coherence Tomography Angiography Measurements in Patients with Retinal Vein Occlusion. *Korean J Ophthalmol* 2021; 35(2):159-167.

15. Asato T, Nagai N, Suzuki M, Uchida A, Kurihara T, Ban N, Minami S, Shinoda H, Tsubota K, Ozawa Y. Closure of macular hole secondary to ischemic hemi-central retinal vein occlusion by retinal photocoagulation and topical anti-inflammatory treatment. *Lasers Med Sci* 2021;36(2):469-71.
16. Mirzania D, Thomas A S, Stinnett S, et al. Differences in Presentation and Outcomes in Males and Females With Branch Retinal Vein Occlusion. *Ophthalmic Surg Lasers Imaging Retina* 2020; 51(10):564-572.
17. Lee S J, Chang W C . Comparison of Intravitreal Dexamethasone Implant and Bevacizumab Injection for Branch Retinal Vein Occlusion with Macular Edema According to Macular Perfusion. *J Retina*, 2020; 5(2):135-142.
18. Ahn J, Sohn J H, Kong M . Optical Coherence Tomography Angiography Features of Idiopathic Macular Telangiectasia Type 2 and Macular Branch Retinal Vein Occlusion. *J Retina*, 2020; 5(1):44-51.
19. Vader M, Schauwvlieghe N, Verbraak F D, et al. Comparing the efficacy of bevacizumab and ranibizumab in patients with retinal vein occlusion: the BRVO study, a randomized trial. *Ophthalmol Retina* 2020; 4(6):576-587.
20. Yagisawa K, Baba T, Kaiho T, et al. The Use of Inner Retinectomy to Relieve Inner Retinal Foreshortening Causing Retinal Detachment in the Setting of Branch Retinal Vein Occlusion. *Case Rep Ophthalmolog Med* 2020; 2020(2):1-5.
21. Hashmi K, Al-Ghafri F, Pathare A . Role of thrombophilia testing in retinal vein occlusion: single centre experience from Oman. *India J Clin Exp Ophthalmol* 2020;6(4):497-500.
22. Li S, Pan J, Ji J, et al. Numerical Simulation of Thrombolysis in Robot-Assisted Retinal Vein Cannulation. *Complexity* 2020; 2020(4):1-12.
23. Alavi M, Adulrahman NA, Haleem A A, Al-Rawanduzi ADH, Khusro A, Abdelgawad MA, Ghoneim MM, Batiha GES, Kahrizi D, Martinez F. et al. Nanoformulations of curcumin and quercetin with silver nanoparticles for inactivation of bacteria. *Cell Molr Biol* 2022;67(5), 151–156. <https://doi.org/10.14715/cmb/2021.67.5.21>.
24. Iqbal MJ, Ali S, Rashid U, Kamran M, Malik MF, Sughra K, Zeeshan N, Afroz A, Saleem J, Saghir M. Biosynthesis of silver nanoparticles from leaf extract of *Litchi chinensis* and its dynamic biological impact on microbial cells and human cancer cell lines. *Cell Molr Biol* 2018;64(13):42-7. <https://doi.org/10.14715/cmb/2018.64.13.9>
25. Ibrahim KH, Ali FA, Sorchee SM. Biosynthesis and characterization with antimicrobial activity of TiO₂ nanoparticles using probiotic *Bifidobacterium bifidum*. *Cell Molr Biol* 2020;66(7):111-7. <https://doi.org/10.14715/cmb/2020.66.7.17>