

The effects of Shikonin on the hypertrophic scar of rabbit ears via the TLR4/NF- κ B signaling pathway

Chang Liu¹, Hailong Zhang¹, Xiaoqian Cui¹, Shanshan Wang¹, Quanyu Zhou^{2*}¹Department of Dermatology, First Affiliated Hospital of Heilongjiang University of Chinese Medicine, Harbin, 150040, China²Department of Traditional Chinese Medicine, The 5th People's Hospital of Foshan City, Foshan, 528211, China

ARTICLE INFO

Original paper

Article history:

Received: May 14, 2023

Accepted: July 22, 2023

Published: September 30, 2023

Keywords:

shikonin, hypertrophic scar, NF- κ B/TLR4

ABSTRACT

As a traditional Chinese medicine, Zihuang Shengji Ointment has obvious effects on promoting postoperative wound healing and reducing scar formation in clinical application. Shikonin is the major phytochemical in Zihuang Shengji Ointment. As a kind of naphthoquinone compound with anti-tumor, anti-viral, anti-inflammatory, anti-bacterial and other biological activities extracted from *Lithospermum erythrorhizon*, shikonin exerts an important role in many diseases. Shikonin has impacts on the development of hypertrophic scars (HS), however, these effects are yet mostly unknown. As a result, we created the Newland white rabbit ear HS model, administered shikonin to it, and then assessed scar hypertrophy using HE and VG staining. The degree of scarring is assessed by HI, NA, as well as AA. The expression levels of collagen I, collagen III, as well as α -SMA as well as fibroblast proliferation, are also measured using real-time PCR, immunohistochemistry, and western blot. TUNEL tests are used to assess fibroblast apoptosis. In our work, HE staining and VG staining showed that the shikonin-treated group had normal bundles of collagen fibers and regular fibroblasts. Shikonin suppresses the production of HS, according to histopathological features, HI, NA, and AA measures. Shikonin also causes fibroblast apoptosis and lowers the production of α -SMA, collagen I, as well as collagen III in the HS rat. Notably, we discover that NF- κ B activation and TLR4 activity are inhibited by shikonin. Overall, the results show that the signaling pathway of TLR4/NF- κ B is modulated by shikonin's inhibitory effect on scar formation, which represses the levels of collagen I, collagen III, α -SMA, as well as fibroblasts.

Doi: <http://dx.doi.org/10.14715/cmb/2023.69.9.24>Copyright: © 2023 by the C.M.B. Association. All rights reserved. 

Introduction

Hypertrophic scar (HS) is a pathological change of skin appearance and function during wound repair. The major features of HS include excessive deposition of extracellular matrix secreted by fibroblasts and metabolic disorders of extracellular matrix proteins based on collagen, such as collagen I and collagen III (1, 2). Macroscopically, the skin surface is bright red, with local thickening and hardening, overgrowth, protruding from the normal skin surface (3). Currently, treatment of HS mainly includes drugs, compression, radiation, laser, and surgery, but the effect is limited (4, 5). As a result, it is urgent to explore new drugs and strategies for treating HS.

HS fibroblasts are the main effector cells in wound healing progression which leads to scar hyperplasia (6). Therefore, inhibiting fibroblasts is critical for preventing scar formation. In clinical practice, glucocorticoid, such as triamcinolone acetonide, compound betamethasone injection, alone or in combination with other drugs, such as 5-FU, is one of the common methods to treat hypertrophic scar (7). The side effects compensate for the benefits of 5-FU. Thus, the development of novel medicines to treat HS has gained increasing popularity.

Shikonin, as the active ingredient of Zihuang Shengji Ointment, is a kind of natural naphthoquinone extracted from the root of *Arnebiae Radix* (Fig. 1). Previous study

reveals that shikonin has anti-inflammatory, antibacterial, immunomodulatory, anti-cancer, and anti-virus effects (8, 9). Consequently, several publications examined the possible applicability of Shikonin, for instance, has been discovered by Liu *et al.* to stimulate cell death and autophagy in human melanoma through ROS-regulated endoplasmic reticulum stress/p38 pathways (10). Shikonin has reportedly been shown to slow HS development and enhance its appearance (11). Additionally, it has been noted that shikonin influences fibroblasts' biological function to enhance HS (12). To the best of our knowledge, no one has described the molecular process. This study investigated the molecular mechanism of shikonin during HS repair. The

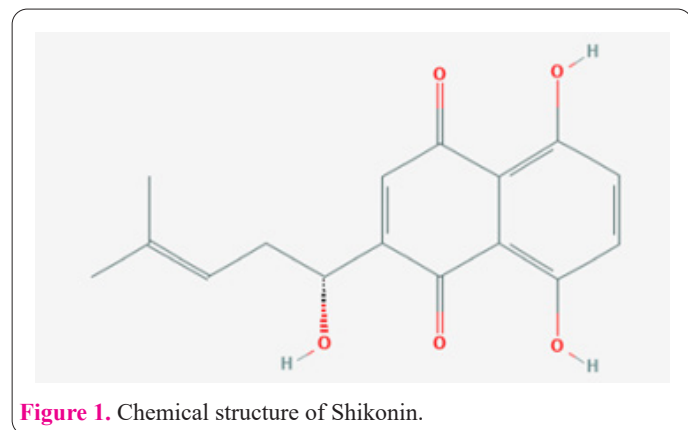


Figure 1. Chemical structure of Shikonin.

* Corresponding author. Email: yuquanzhoumm@163.com

paper may provide a theological basis for the application of shikonin to HS.

Materials and Methods

Creation and treatment of rabbit ear hypertrophic scar model

A total of 36 New Zealand white rabbits (8-9 weeks, 1.5-1.8 kg) were bought from Jiagan (Shanghai, China). Every rabbit was housed in a separate cage with unrestricted access to normal food and water at a constant temperature (24-26°C). The Animal Experimentation Ethics Committee of the First Affiliated Hospital of Heilongjiang University of Chinese Medicine gave their approval to all animal experiments.

Shikonin was purchased from MedChemExpress (MCE, NH, USA). Six groups of rabbits were created at random: b-FGF group (positive control), low-concentration shikonin group (0.5%), medium-concentration shikonin group (1%), high-concentration shikonin group (2%), and control group. Based on earlier research, the rabbit ear HS modeling was enhanced (13). In a nutshell, rabbits were caged for a week before being anesthetized at the ear margin with pentobarbital sodium (30 mg/kg). On the ventral side of each rabbit ear, four 1-cm-diameter spherical incisions were produced to avoid blood vessels using a stringent aseptic method. The full-thickness skin was excised to the surface of the soft bone, and the interval between each wound was about 1.5cm. There were 8 wounds in each rabbit. Twenty-one days after the operation, the wound healed and prominently protruded from the skin surface, forming a hypertrophic scar (Fig. 2). Shikonin groups received varied concentrations of shikonin applied twice daily, while the b-FGF group received b-FGF from the fourth week until the end of the seventh week. The matrix group's scar was lightly treated with matrix paste cream twice daily. All animals were sedated and murdered after the seventh week in preparation for the experiments to come.

HE staining

Rabbit ear scar tissues were collected, then fixed in 10% formalin, encased in paraffin, and cut into slices for HE and VG staining. Before spending 15 minutes in a HE solution, the slices underwent dewaxing and hydration.

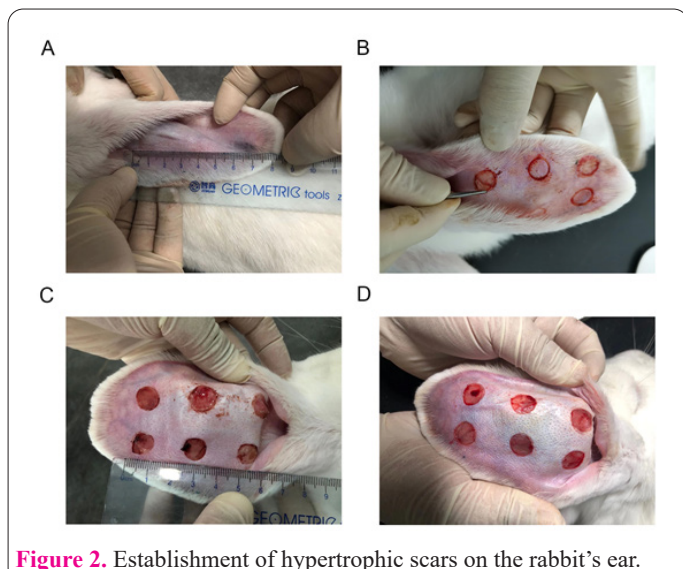


Figure 2. Establishment of hypertrophic scars on the rabbit's ear.

Without a doubt, the hypertrophy index (HI), numerical densities of fibroblasts on the area (NA), and area density of collagen fibers (AA) were determined after the pathological features of the rabbit ear were studied under a light microscope (Olympus, Tokyo, Japan).

VG staining

Weigert's hematoxylin solution was applied to rabbit ear tissues for 20 minutes after a thorough water wash, dewaxing, and staining. The slices were then stained with Van Gieson solution for one minute after being rinsed with running water for ten minutes. The parts were finally dried off, cleaned, and sealed. Utilizing Image Pro Plus software 6.0 (Media Cybernetics, Washington, DC, USA), the slices were then viewed under a light microscope and scored.

Immunohistochemical (IHC) analysis

The presence of PCNA, Ki-67, Collagen I, and Collagen III, as well as α -SMA, was determined by IHC analysis. Sections of the rabbit ears were dewaxed and hydrated. Sections were then cleaned with PBS before being sealed with H_2O_2 for 5-10 minutes. After antigen repair, slices of tissues were treated with goat serum sealant and let to remain at room temperature for 20 minutes. The primary antibody was then applied to the slices for an overnight duration at 4°C. The sections were then incubated with the secondary antibody for an additional hour at room temperature. After washing off the secondary antibody, the sections were first stained with DAB for 5-10 minutes, followed by a 2-minute counterstain with hematoxylin. The slices were then sealed, made transparent, and dried before being viewed under a microscope.

TUNEL assay

A prior work (11) employed the TUNEL test to assess the level of apoptosis in the rabbit ear scar.

qRT-PCR analysis

TRIzol reagents (Invitrogen, Shanghai, China) were used to extract RNA from cell and tissue samples. We employed the Takara, Otsu, Shiga, Japan company's PrimeScriptTMII 1st Strand cDNA Synthesis Kit to induce cDNA. qPCR analysis was performed via the SYBR® green main mixture and a real-time fluorescence quantitative PCR instrument (Bio-RAD, CA, USA). The primers for RT-qPCR are displayed in Table 1.

Table 1. Primer sequences used for qRT-PCR

Genes		Primer sequences (5'-3')
Bax	Forward	AAACTGGTGCTCAAGGCC
	Reverse	TGAGGAGTCTCACCCAACCA
Bcl-2	Forward	CCCACCCCTGGCATCTTC
	Reverse	GCGACGGTAGCGACGAGA
Collagen I	Forward	GGCTGCCTGCTTCCTGTAACCC
	Reverse	CATCCTCGGCTGGTCGAGGATA
Collagen III	Forward	TGGTGTGGAGCCGCTGCCA
	Reverse	CTCAGCACTAGAATCTGTCC
α -SMA	Forward	CTGCTGAGCGTGAGATTGTC
	Reverse	CTCAAGGGAGGATGAGGATG
β -actin	Forward	GTGACGTTGACATCCGTAAGA
	Reverse	GCCGGACTCATCGTACTCC

Western blot analysis

RIPA lysis buffer was employed to extract all of the protein. Using a BCA protein assay kit from Thermo Fisher in Massachusetts, USA, the protein content was assessed following protein extraction. The protein samples were added, separated on a 10% Bis-Tris gel, and then transferred to PVDF membranes. The membranes were incubated with primary antibodies at 4°C for a whole night after being blocked with 5% non-fat milk. The membranes were then exposed to an HRP-conjugated secondary antibody for two hours at room temperature (1:5000 dilution). To identify PVDF membranes, a western blotting substrate with ECL (Vazyme, Nanjing, China) was applied. Protein bands were determined objectively using Image J software. We bought antibodies from Abcam (Cambridge, UK) against Bax (1:1000), Bcl-2 (1:2000), collagen I (1:1000), and collagen III (1:1000). Proteintech (Wuhan, China) provided the α -SMA (1:1000), TLR4 (1:500), as well as β -actin (1:10000) utilized in the experiment. We bought p-NF κ B and NF- κ B from Santa Cruz (1:500, CA, USA).

Statistical analysis

Outcomes from three separate tests were gathered. Each outcome was displayed as mean \pm SD. The data were analyzed with GraphPad Prism 7.0 (GraphPad Inc., San Diego, CA, USA) by one-way ANOVA and the t-test. At $P < 0.05$, statistics were deemed significant.

Results

Histomorphology of shikonin on the hypertrophic scar in rabbit ears

All wounds had entirely epithelialized and had surgical scars by the end of the 21st day. By the conclusion of the seventh week, each group had developed hypertrophic scar tissue (Fig. 3A). The hypertrophic scar in the control group as well as matrix groups was more noticeable than the surrounding tissue, as seen in Fig. 3B, although there were no discernible differences between the groups. In contrast, the hypertrophic scar treated with various concentrations of either shikonin or b-FGF exhibited flatter and softer tissue, notably in the group treated with medium doses of both. There was no discernible difference between the two groups. To learn more about the effects of shikonin on the hypertrophic scar, HE staining was done. The outcomes demonstrated that the scars in the control group as well as the matrix group had the dermis layer with ridges, angiogenesis, and irregular fibroblasts present, whereas the scars in the treatment group had substantially less of these features (Fig. 3C).

Additionally, VG staining demonstrated that collagen fibers in the treatment group, particularly the medium concentration shikonin and b-FGF group, could be distinguished from the control and matrix groups by being denser, thicker, and more disorganized (Fig. 3D). However, there were no appreciable variations between the matrix and control groups. The treatment group's scar elevation indices (HI, NA, and AA) were considerably lower than those of the control and matrix groups, but they did not differ dramatically from those of the control group and matrix group (Fig. 3E). All these results demonstrated that medium concentration shikonin had an effective therapeutic agent for HS similar to b-FGF.

Effects of shikonin on scar fibroblasts proliferation and apoptosis

The effects of shikonin on the proliferation and apoptosis of scar fibroblasts in rabbit ears were next examined. In contrast to the control and matrix groups, shikonin and b-FGF-treated groups showed a substantial reduction in the proliferation-related proteins PCNA and Ki-67 when compared to the control and matrix groups (Fig. 4A, 4B).

TUNEL labeling showed that the matrix did not affect the apoptosis of the cells. Shikonin and b-FGF enhanced

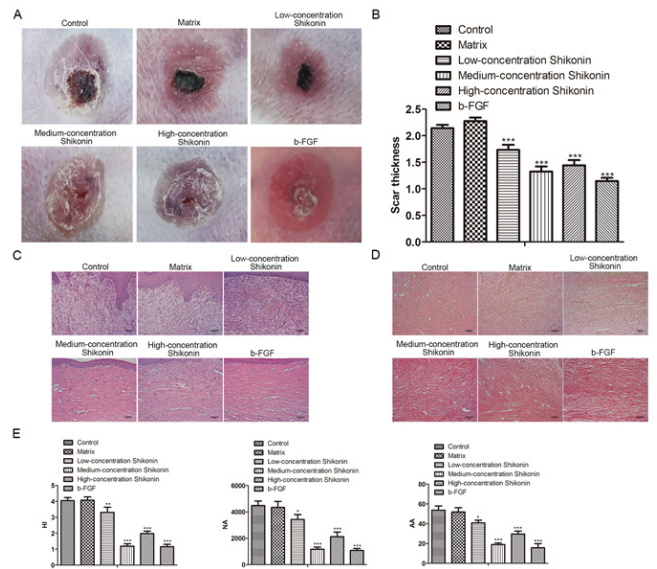


Figure 3. Shikonin histomorphology on the hypertrophic scar in rabbit ears. (A). Macroscopic image of the hypertrophic scar on the rabbit's ear in the groups of b-FGF, low-concentration shikonin, medium-concentration shikonin, and high-concentration shikonin. (B). The thickness of the scar on the rabbit's ear. (C). HE staining for the scar on a rabbit's ear. (D). Van Gieson staining for the scar on the rabbit's ear. (E). The HI, NA and AA of rabbit's ear scar. * $P < 0.05$, ** $P < 0.01$, # $P < 0.05$, ## $P < 0.01$ compared with the corresponding control group.

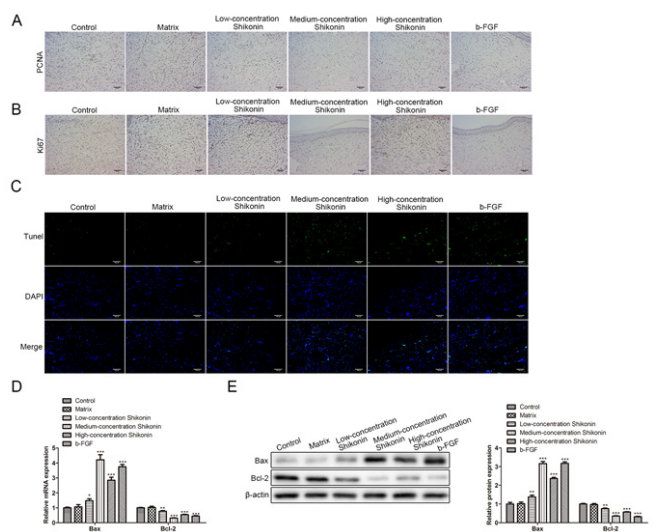


Figure 4. Effects of shikonin on scar fibroblast proliferation and apoptosis. (A). PCNA protein expression on rabbit hypertrophic scars measured by IHC. (B). Ki-67 protein expression on rabbit hypertrophic scars measured by IHC. (C). Cell apoptosis was assessed by TUNEL staining. (D). Relative mRNA expression of Bax and Bcl-2. (E). Relative protein expression of Bax and Bcl-2. # $P < 0.05$, ## $P < 0.01$ compared with the corresponding control group.

scar cell apoptosis in rabbit ears compared to the control and matrix groups, although there were no appreciable differences between them (Fig. 4C). Furthermore, in the shikonin and b-FGF groups in comparison with the control and matrix group, the expression of Bax was dramatically elevated while Bcl-2 was downregulated (Fig. 4D, 4E), particularly in the medium-concentration shikonin. These findings demonstrated how shikonin reduced the growth of scar fibroblasts and increased apoptosis in rabbit ears.

Effects of shikonin on collagen synthesis and decomposition

The production and breakdown of collagen were important in the development of the scar. In contrast to the control and matrix groups, IHC results showed that shikonin and b-FGF dramatically decreased the expression of Collagen I, Collagen III, as well as α -SMA (Fig. 5A). Additionally, the outcomes of the western blot analysis and qRT-PCR were comparable (Fig. 5B, 5C). These outcomes showed that shikonin controlled the synthesis and breakdown of scar collagen.

Effects of shikonin on TLR4/NF- κ B pathway

Subsequently, we investigated the associated signaling pathways. We found that the protein levels of TLR4 and p-NF- κ B were significantly downregulated in the shikonin and b-FGF-treated group, compared with control and matrix groups (Fig. 6), suggesting that shikonin might work through TLR4/NF- κ B pathway.

Discussion

HS formation results from excessive fibroblast proliferation, redundant extracellular matrix and collagen deposition caused by abnormal reactions during wound healing (14). Because of a limited understanding of the pathogenesis, treatment of HS remains a significant challenge in the clinic (15). Currently, surgical procedures, nonsurgical procedures such as pulsed-dye laser ablation, intralesional steroid therapy, and combinations of surgical and nonsurgical procedures are not satisfying owing to their inconvenience, expense, or adverse effects. (16, 17). Therefore, it was necessary to explore new therapeutic methods and drugs for HS treatment. Due to the similarity of the rabbit ear HS model and human HS, it is often used in anti-scar forming research (13, 18).

Numerous phytochemicals are extracted from traditional Chinese medical herbs (19, 20), and exert a key role in various diseases. For example, Artemisinin as an active substance against malaria is obtained from *Artemisia carvifolia*, which has saved many lives in Africa (21). Ginsenoside Rg3, isolated from traditional medicinal Ginseng, has been found a therapeutic effect on the hepatitis C virus (HCV) via inhibiting HCV proliferation and reversing HCV aberrant mitochondrial dynamics (22). As a kind of naphthoquinone compound with strong lipid solubility extracted from the traditional Chinese medicine *Lithospermum erythrorhizon*, shikonin has antitumor, anti-inflammatory, antiviral, and antibacterial effects (23). In addition, Papageorgio *et al.* first prove the efficacy of shikonin in healing skin wounds (24, 25). Chen Fan *et al.* find that shikonin inhibits the proliferation of skin fibroblasts and keratinocytes through ERK1/2, JNK1/2 and P38 α / β signaling pathways, and regulates the expressions of bel-2 and

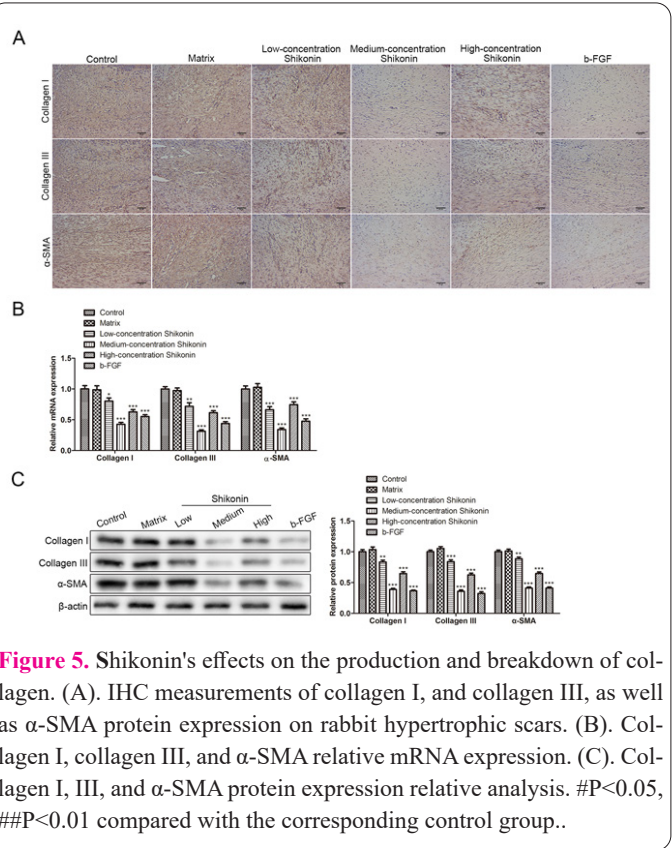


Figure 5. Shikonin's effects on the production and breakdown of collagen. (A). IHC measurements of collagen I, and collagen III, as well as α -SMA protein expression on rabbit hypertrophic scars. (B). Collagen I, collagen III, and α -SMA relative mRNA expression. (C). Collagen I, III, and α -SMA protein expression relative analysis. #P<0.05, ##P<0.01 compared with the corresponding control group..

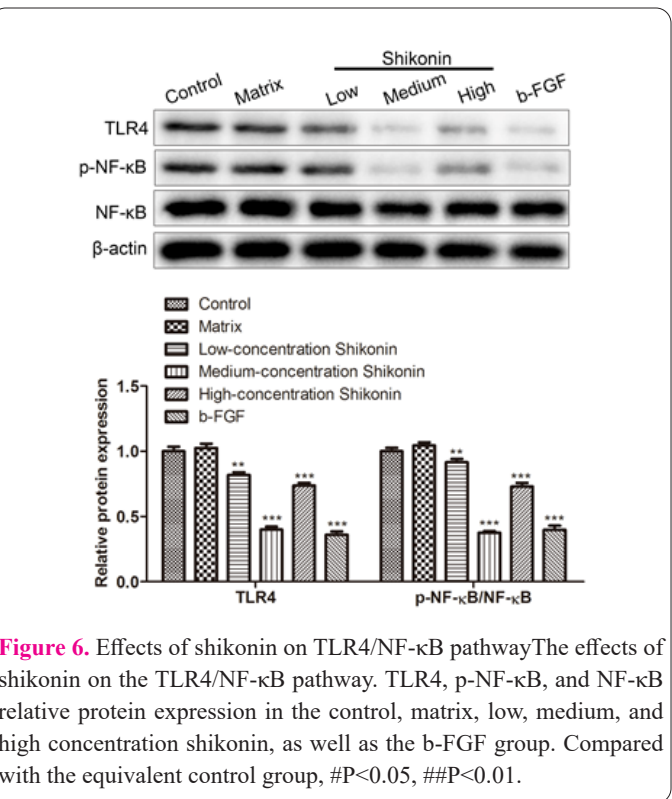


Figure 6. Effects of shikonin on TLR4/NF- κ B pathway. The effects of shikonin on the TLR4/NF- κ B pathway. TLR4, p-NF- κ B, and NF- κ B relative protein expression in the control, matrix, low, medium, and high concentration shikonin, as well as the b-FGF group. Compared with the equivalent control group, #P<0.05, ##P<0.01.

Caspase-3 through P-ERK (11, 26). In this investigation, we discovered that shikonin significantly reduced fibroblast in the dermis, according to the histological analysis. Furthermore, shikonin increased fibroblast mortality and lowered fibroblast proliferation as well as collagen production and deposition. Additionally, in a dose-dependent way, it decreased AA, NA, and HI.

Toll-like receptor 4 (TLR4), a member of the innate immune system and a pathogen pattern recognition receptor is the natural receptor of LPS (27). TLR4 can be utilized as a marker for wounds since Gram-negative bacteria

frequently contribute to the development of wounds and produce a significant quantity of LPS. TLR4 is crucial for controlling the acute inflammatory response, cell signaling, and cell death (28). Consequently, it makes sense to assume that TLR4 may have a significant regulatory function in the development of HS. TLR4 activates two distinct downstream signaling pathways—MAPK and NF- κ B pathways—when it interacts with the ligand. Pro-inflammatory substances including TNF- α and IL-1 β are produced and released as a result of NF- κ B activation (29). Shikonin dramatically reduced the upregulation of TLR4 and NF- κ B caused by HS in our research in a dose-dependent manner, demonstrating that shikonin may control the development of HS through the TLR4/NF- κ B pathway.

In summary, our research showed that shikonin inhibited fibroblast proliferation, collagen synthesis and deposition, and promoted fibroblast apoptosis to improve HS via the TLR4/ NF- κ B pathway. Our finding supported the potential of Shikonin as a drug for HS treatment.

Interest conflict

The authors declare that there are no conflicts of interest.

Consent for publications

The author read and proved the final manuscript for publication.

Availability of data and material

All data generated during this study are included in this published article

Authors' contribution

Chang Liu and Quanyu Zhou contributed to the study design. Hailong Zhang, Xiaoqian Cui, and Shanshan Wang performed the experimental procedures and data collection, and all the authors performed the statistical analysis. Chang Liu wrote the initial manuscript. Quanyu Zhou revised the final manuscript. All the authors reviewed and agreed to the final manuscript.

Funding

This article was achieved based on the grant support of the Traditional Chinese Medicine Research Project of Heilongjiang Province (ZYW2022-097), which the authors thank.

Ethics approval and consent to participate

The study protocol of animals was approved by the Ethics Committee of the First Affiliated Hospital of Heilongjiang University of Chinese Medicine.

References

1. Wietecha MS, Pensalfini M, Cangkrama M, et al. Activin-mediated alterations of the fibroblast transcriptome and matrisome control the biomechanical properties of skin wounds. *Nat Commun* 2020; 11(1):2604.
2. Sidgwick GP, Bayat A. Extracellular matrix molecules implicated in hypertrophic and keloid scarring. *J Eur Acad Dermatol Venerol* 2012; 26(2):141-52.
3. Song Y, Yu Z, Song B, et al. Usnic acid inhibits hypertrophic scarring in a rabbit ear model by suppressing scar tissue angiogenesis. *Biomed Pharmacother* 2018; 108:524-30.
4. Gold MH, McGuire M, Mustoe TA, et al. Updated international clinical recommendations on scar management: part 2--algorithms for scar prevention and treatment. *Dermatol Surg* 2014; 40(8):825-31.
5. Gauglitz GG, Korting HC, Pavicic T, Ruzicka T, Jeschke MG. Hypertrophic scarring and keloids: pathomechanisms and current and emerging treatment strategies. *Mol Med* 2011; 17(1-2):113-25.
6. Weng W, He S, Song H, et al. Aligned Carbon Nanotubes Reduce Hypertrophic Scar via Regulating Cell Behavior. *ACS Nano* 2018; 12(8):7601-12.
7. Ogawa R. The most current algorithms for the treatment and prevention of hypertrophic scars and keloids. *Plast Reconstr Surg* 2010; 125(2):557-68.
8. Guo C, He J, Song X, et al. Pharmacological properties and derivatives of shikonin-A review in recent years. *Pharmacol Res* 2019; 149:104463.
9. Jeziorek M, Syklovska-Baranek K, Pietrosiuk A. Hairy Root Cultures for the Production of Anti-cancer Naphthoquinone Compounds. *Curr Med Chem* 2018; 25(36):4718-39.
10. Liu Y, Kang X, Niu G, et al. Shikonin induces apoptosis and pro-survival autophagy in human melanoma A375 cells via ROS-mediated ER stress and p38 pathways. *Artif Cells Nanomed Biotechnol* 2019; 47(1):626-35.
11. Xie Y, Fan C, Dong Y, et al. Functional and mechanistic investigation of Shikonin in scarring. *Chem Biol Interact* 2015; 228:18-27.
12. Nie Y, Yang Y, Zhang J, et al. Shikonin suppresses pulmonary fibroblasts proliferation and activation by regulating Akt and p38 MAPK signaling pathways. *Biomed Pharmacother* 2017; 95:1119-28.
13. Morris DE, Wu L, Zhao LL, et al. Acute and chronic animal models for excessive dermal scarring: quantitative studies. *Plast Reconstr Surg* 1997; 100(3):674-81.
14. Song J, Li X, Li J. Emerging evidence for the roles of peptide in hypertrophic scar. *Life Sci* 2020; 241:117174.
15. Kravez E, Villiger M, Bouma B, et al. Prediction of Scar Size in Rats Six Months after Burns Based on Early Post-injury Polarization-Sensitive Optical Frequency Domain Imaging. *Front Physiol* 2017; 8:967.
16. Finnerty CC, Jeschke MG, Branski LK, et al. Hypertrophic scarring: the greatest unmet challenge after burn injury. *Lancet* 2016; 388(10052):1427-36.
17. Zhao JC, Zhang BR, Shi K, et al. Lower energy radial shock wave therapy improves characteristics of hypertrophic scar in a rabbit ear model. *Exp Ther Med* 2018; 15(1):933-9.
18. Xiao Z, Qu G. Effects of botulinum toxin type a on collagen deposition in hypertrophic scars. *Molecules* 2012; 17(2):2169-77.
19. Wang CZ, Li P, Yuan CS. Traditional Chinese herbal therapy as a treatment option for H1N1 influenza. *Ann Intern Med* 2012; 156(2):166; author reply -7.
20. Miller LH, Su X. Artemisinin: discovery from the Chinese herbal garden. *Cell* 2011; 146(6):855-8.
21. Tu Y. Artemisinin-A Gift from Traditional Chinese Medicine to the World (Nobel Lecture). *Angew Chem Int Ed Engl* 2016; 55(35):10210-26.
22. Kim SJ, Jang JY, Kim EJ, et al. Ginsenoside Rg3 restores hepatitis C virus-induced aberrant mitochondrial dynamics and inhibits virus propagation. *Hepatology* 2017; 66(3):758-71.
23. Andujar I, Rios JL, Giner RM, Recio MC. Pharmacological properties of shikonin - a review of literature since 2002. *Planta Med* 2013; 79(18):1685-97.
24. Papageorgiou VP, Assimopoulou AN, Ballis AC. Alkannins and shikonins: a new class of wound healing agents. *Curr Med Chem* 2008; 15(30):3248-67.
25. Karayannopoulou M, Tsioli V, Loukopoulos P, et al. Evaluation of

- the effectiveness of an ointment based on Alkannins/Shikonins on second intention wound healing in the dog. *Can J Vet Res* 2011; 75(1):42-8.
26. Fan C, Dong Y, Xie Y, et al. Shikonin reduces TGF-beta1-induced collagen production and contraction in hypertrophic scar-derived human skin fibroblasts. *Int J Mol Med* 2015; 36(4):985-91.
27. Ermertcan AT, Ozturk F, Gunduz K. Toll-like receptors and skin. *J Eur Acad Dermatol Venereol* 2011; 25(9):997-1006.
28. Laird MH, Rhee SH, Perkins DJ, et al. TLR4/MyD88/PI3K interactions regulate TLR4 signaling. *J Leukoc Biol* 2009; 85(6):966-77.
29. Li XP, Liu P, Li YF, et al. LPS induces activation of the TLR4 pathway in fibroblasts and promotes skin scar formation through collagen I and TGF-beta in skin lesions. *Int J Clin Exp Pathol* 2019; 12(6):2121-9.