

Original Article

Molecular mechanism of the influence of related genes expression in synovium tissue around shoulder joint of secondary frozen shoulder model rats on angiogenesis

Jie Xu^{1,2}, Dong Ren¹, Fei Liu², Shuren Liu³, Pengcheng Wang^{1,*}¹ Orthopaedic Trauma Service Centre, The Third Hospital of Hebei Medical University, Shijiazhuang 050051, China² Joint Surgery, The First Hospital Of Qinhuangdao, Qinhuangdao 066000, China³ Spine Surgery, The Chest Hospital of Hebei, Hebei, Shijiazhuang 050051, P.R. China

Article Info

Abstract



Article history:

Received: January 24, 2024

Accepted: April 13, 2024

Published: May 31, 2024

Use your device to scan and read the article online



The study aimed to explore the pathogenesis of secondary frozen shoulder and its influence on synovium tissue and angiogenesis by constructing a rat secondary frozen shoulder model along with transforming growth factor. 40 healthy male rats aged 8 weeks were divided into Sham group (n=10, no modeling treatment), Control group (n=10, modeling treatment), Low group (n=10, modeling treatment, and 10 mL/d transforming growth factor), and High group (n=10, modeling treatment, and 20 mL/d transforming growth factor). Hematoxylin and Eosin (HE) method was used for histological detection, and Reverse Transcription-Polymerase Chain Reaction (RT-PCR) and immunohistochemical staining method were adopted to detect the expression of Matrix metalloproteinase-14 (MMP-14), mitogen-activated protein kinase (p38MAPK), and Vascular endothelial growth factor (VEGF). Compared with Sham group, the range of abduction and external rotation of rat glenohumeral joint in Control group, Low group, and High group was significantly reduced, and High group had the smallest range. Compared with the Sham group, the synovium in the Control group, the Low group, and the High group had obvious hyperplasia, and the blood vessels were significantly increased. Immunohistochemical staining and RT-PCR results showed that compared with Sham group, MMP-14, p38 MAPK, and VEGF in Control group, Low group, and High group all increased significantly, among which High group increased most. The secondary frozen shoulder is mainly manifested as synovial hyperplasia and increased blood vessels, which are related to the induction of MMP-14, p38 MAPK, and VEGF by transforming growth factor, which reveals the pathogenesis of secondary frozen shoulder to a certain extent, and lays a foundation for subsequent clinical treatment of secondary frozen shoulder.

Keywords: Secondary frozen shoulder; Transforming growth factor; MMP-14; p38 MAPK; VEGF

1. Introduction

The concept of frozen shoulder was first proposed by Codman in 1934. He called the weakened shoulder joint rotation activity or shoulder joint mucosal adhesion caused by various factors as frozen shoulder, and subsequent scholars classified it into specific factors and divided them into internal factors and external factors, and then divided it into primary frozen shoulder and secondary frozen shoulder [1, 2]. Secondary frozen shoulder is mostly caused by intra-articular injury, extra-articular injury, joint capsule lesions, etc. On this basis, scholars have further conjectured that inflammatory factors may be related to the fibrosis of the shoulder joint and bursa [3, 4]. Current studies have shown that transforming growth factor and platelet-derived growth factor are one of the important promoting factors for joint capsule fibrosis. In addition, studies have shown that metalloproteinases are related to joint capsule fibrosis and synovial proliferation [5]. The increase of matrix metalloproteinases leads to the depo-

sition of extracellular matrix collagen, the reduction of collagen degradation, the accumulation of type I and type III collagen, the fibrosis of the joint capsule, and finally the symptoms of frozen shoulder [6]. At present, the treatment of secondary frozen shoulder is mostly conservative treatment in the early stage and surgical treatment in the late stage [7]. Conservative treatment is mainly achieved by injecting steroids into the shoulder joint cavity, but the effect of conservative treatment is not significant and the cycle is relatively long. At the same time, patients need to pay attention to exercise activities to get a better effect [8]. However, late surgical treatment often leads to other injuries in the shoulder joint such as rotator cuff, and superior labrum from anterior to posterior (SLAP) injury [9]. Therefore, it is of certain urgency to elaborate on the pathological mechanism of secondary frozen shoulder and obtain new treatment methods through this.

Therefore, in the study, the rat secondary frozen shoulder model was established. Then the physiological cha-

* Corresponding author.

E-mail address: Wangpc999@hebmu.edu.cn (P. Wang).Doi: <http://dx.doi.org/10.14715/cmb/2024.70.5.39>

racteristics of the rat shoulder joint synovium tissue and vascular tissue and the expression of related genes were explored to determine the role of transforming growth factor in the rat secondary frozen shoulder model, which explains clinical mechanism of secondary frozen shoulder and lays a foundation for subsequent treatment.

2. Materials and Methods

2.1. Experimental animals and grouping

40 healthy SD rats (Hebei Medical University Animal Experiment Research Center) were selected, which were required to be healthy males, 8 weeks old, weighing 200-300 g, with an average weight of 260 ± 21 g.

SD rats were provided by Hebei Medical University Experimental Animal Centre. All experiments were performed in accordance with the guidelines for the Care and Use of Experimental Animals (National Research Committee, 1996) and approved by the Ethics Committee for the Use of Experimental Animals of Hebei Medical University (approval no. Z2019-012-1; Hebei, China). The rats were raised in a clean environment at a room temperature of about 25°C and a relative humidity of about 60%, and allowed to eat and drink freely to adapt for one week. The rats were randomly divided into 4 groups, each with 10 rats: Sham group, Control group, Low group, High group. The animal handling and experimental procedures during the experiment were in compliance with the National Laboratory Animal Standards.

2.2. Major instruments

The main experimental instruments included inverted fluorescence microscope (from Lecia, Wetzlar, Germany), fluorescence quantitative PCR instrument (Bio-rad, Hercules, CA, USA), cell culture plate (Corning, Corning, NY, USA), electronic analytical balance (Sartorius, Germany), high-speed centrifuge (Bierlofuge, USA), and PCR instrument (USA) Bio-rad Corporation, Hercules, CA, USA).

2.3. Construction of rat frozen shoulder model and group processing

The rat frozen shoulder model was constructed by exercise method [10]. The rats in Control group, Low group, and High group accepted adaptive training before the experiment was officially carried out so that the rats could accept training from slow to urgent on the set running platform. Pre-training lasted for three days, and learning lasted half an hour at the same time point. When all rats in the Control group, Low group and High group had mastered how to exercise on the treadmill, a formal model was constructed. In order to maximize the damage to the rat's shoulder joints during the model construction, the treadmill and the exercise were set at 13 r/min, which was the maximum speed that the rats could withstand during exercises. When the rat was running on the treadmill, its head should be lower than the tail, so as to ensure that the rat's front paw bore the maximum weight and maximize the damage to the rat's shoulder joint. In the formal experiment, training was conducted for 2 hours at the same time every day, 6 times a week, and rats rested on Sunday. The training duration was 4 weeks in total. Sham group did not accept training.

On the basis of daily training, rats in Low group and High group were injected with different concentrations of transforming growth factor ((Rabbit anti-TGF antibody),

America SantaCruz Biotechnology Inc.) into the shoulder joint cavity every week, Low group was injected with 10 mL/d transforming growth factor, and High group was injected with 20 mL/d transforming growth factor, other operations were the same as Control group.

2.4. Evaluation index of the construction of frozen shoulder

Half of the rats in all groups were anesthetized, and 0.35% pentobarbital sodium (0.3 mL / 200 g) was anesthetized by ear margin intravenous injection. After the clipping reflex and pupillary reflex disappeared, the left shoulder hair was cut off with ophthalmic scissors and the skin was disinfected with iodophor. It should put double-layer sterile operation sheet and perform hand washing with sterile gloves routinely. A surgical incision of 1 cm in the left shoulder was made to blunt the skin separation muscle and expose the supraspinatus muscle. The supraspinatus muscle was broken with ophthalmic scissors, the wound was washed with normal saline, and the wound was sutured layer by layer. No treatment was done on the opposite side to avoid the effect of the wound incision on the movement of the rat's opposite mesothelium. The modeling was successful, and the rats were kept in cages after rotator cuff injury. Penicillin was used for three consecutive days after surgery. After 4 weeks of normal feeding, both lateral slip membrane tissues were taken and stored in liquid nitrogen for reserve.

After four weeks of treadmill training, the rats in all groups were killed by asphyxiation, and the bilateral glenohumeral joints of half of the rats in all groups were taken out and their range of motion was measured. The rats were fixed on the experimental table, the upper limbs were removed after the chest wall of the shoulder blade was cut off. Then the fur was removed, and the rat's shoulder blade was fixed on the edge of the square rat plate so that the glenohumeral joint could move normally on the plate without being affected by the plate. The rat humeral head was used as a center to move the glenohumeral joint, a 10 g weight was hung on the humeri, and forward flexion and extension activities were performed on this basis. This activity was similar to the abduction of the human shoulder joint, and the scope of activity was recorded. Subsequently, the rats were in the neutral position, and the humeri were fixed. Then a 10g weight was hung on the forelimb and external rotation activity was performed under this traction. This activity was similar to the external rotation activity of the human shoulder joint abduction, and the range of motion and the degree of motion were recorded by a protractor.

2.5. HE staining and immunohistochemical staining

HE staining: 4 μ m thickness synovium tissue and vascular tissue sections were made, and the slices were taken out and copied. Then HE staining was performed, and the specific operations were as follows. The paraffin sections were dewaxed with xylene solution, dehydrated with gradient alcohol for 5 seconds and then washed with water. After hematoxylin staining for 5-10 minutes, the excess dye solution was washed away, and then hydrochloric acid and glycolic acid were used for acidification. After that, the sections were dyed with eosin solution for 3-5 minutes to wash off the excess dye solution. The gradient ethanol was used for dehydration and clearing for 5 seconds. Then the slices were dried overnight. Finally, they were obser-

ved and images were taken under an optical microscope.

Immunohistochemical staining was performed as follows. After 3 days of treatment, the rats in each group were sacrificed by 4% paraformaldehyde cardiac perfusion. The brain tissues of the rats in each group were obtained under aseptic conditions, and the paraffin sections of the brain tissues were prepared. Paraffin sections were taken from the brain tissues of each group and baked in an incubator at 60°C for 45 min. Then the rats were soaked in xylene I and xylene II solutions for 10 min and 15 min, respectively. Tissues were soaked in 100% ethanol solution for 2 min (twice), followed by 95%, 80%, and 75% ethanol solution for 2 min, and phosphoric acid buffer solution for 5 min (three times). Meanwhile, 3% hydrogen peroxide deionized water was added to incubate them in a constant temperature box for 15 min, which was then washed with phosphoric acid buffer solution for 5 min (3 times). Tissue sections were treated with antigen repair in antigen repair boxes, followed by drops of 50 μ L goat serum blocking solution, incubated in an incubator at 37°C for 30 min, and washed with phosphoric acid buffer for 5 min (3 times). Rabbit anti-mouse Caspase-3I antibody diluted with 1:200 was added and incubated overnight in a 4°C refrigerator. The incubator was reheated for 30 min at 37°C, and antibody II was added. The incubator was incubated for 60 min at 37°C, and the phosphoric acid buffer was washed for 5 min (3 times). The diaminobenzidine (DAB) solution (3% hydrogen peroxide deionized water: goat serum sealing solution =1:20) was used for color development, followed by hematoxylin restaining for 2 min, rinsed with tap water, and dehydrated with gradient ethanol solution. After transparent treatment in xylene solution for 10 min, the film was sealed with neutral resin. The cells with yellow-brown nuclei were regarded as positive cells, and the images were collected under an optical microscope.

Western blot was performed as follows. Kidney tissues of rats in each group were washed with phosphoric acid buffer solution for 2 - 3 times. After tissue homogenization, appropriate amount of lysate was added for processing, and sample proteins were collected. Protein quantification was performed using a BCA protein kit (ThermoFisher, USA), followed by sodium dodecyl sulfate-polyacrylamide gel electrophoresis (SDS-PAGE) gel, protein sampling, electrophoresis, and transmembrane treatment. Diluted rabbit anti-mouse lipopolysaccharide binding protein (LBP) (1:500), CD14 (1:500), JNK (1:500), P38 (1:500), and sheep anti-mouse β -actin (1:500) primary antibody (Bioworld Technology, USA) were added and incubated overnight in a 4°C refrigerator. Goat anti-mouse IgG (1:1000) was added and incubated for 1 h at room temperature. The chemiluminescence of protein bands was collected, and the protein gray value was quantified using ImageJ software.

2.6. RT-PCR detection of related gene expression

The synovium tissue was taken out to the RNA extraction area, and the instructions of the TRIzol kit (Invitrogen, Carlsbad, CA, USA) were followed to extract the total RNA from the tissue. The reverse transcription of the total RNA was performed strictly in accordance with the instructions of the reverse transcription kit. Then they were stored in the tube at -20°C. Real-time PCR (ABI, Foster City, CA, USA) was used to detect the expression of the target gene using synthetic primers from Nanjing

Jinsiri Biotechnology Co., Ltd. (Nanjing, China). B-actin was used as the internal reference gene to detect mRNA expression difference of genes MMP14 (upstream: 5'-TG-GAGAAGAGGGCATTG-3'; downstream: 5'-TTTG-GGACCTGAAGCACA-3), P-P38 MAPK (upstream: 5'-AACAGGATGCCAAGCCATGA-3'; downstream: 5'-GGATCGTGGTACTGGGCAAA-3'), VEGF (upstream: 5'-CGGCGTCGCACTGAACT-3'; downstream: 5'-CAGCCCAGAAGCTTGGACGA-3'), β -actin (upstream: 5'-TTGGGCTGTCCAGATGAGAG-3'; downstream: 5'-CACA CTAGCAGGTCGTCATCAT-3').

2.7. Statistical analysis

In this experiment, the computer software Statistic Package for Social Science (SPSS) version 22.0 (IBM, Armonk, NY, USA) was used for analysis and processing, and the experimental data was expressed by mean standard deviation (mean \pm SD). Variance analysis was used to compare the range of motion in each plane, and t-test was used to compare the range of motion in both glenohumeral joints. In addition, $P < 0.05$ was statistically significant.

3. Results

3.1. The rat frozen shoulder model established

The maximum angle of activity of the glenohumeral joint abduction and external rotation of the rats in each group was measured, and the results are shown in Figure 1. The results showed that compared with the Sham group, the abduction and external rotation angles in the Control group, Low group, and High group all had a significant decrease, and the difference was statistically significant ($P < 0.05$). In the Control group, Low group, and High group, the abduction and external rotation angles of the Low group and the High group were significantly smaller than those of the Control group, and the High group had the smallest abduction and external rotation angles.

3.2. Staining results of HE immunohistochemistry

After HE staining, the synovium tissue of each group of rats was observed under an optical microscope, and the results are shown in Figure 2. In the Sham group, obvious folds can be seen in the synovial membrane of the rat joint capsule, and the folds were more abundant, the protrusions were clearly visible, there was a deeper interstitial groove at the protrusions, the synovial area was larger, and there was no obvious inflammatory cell infiltration in the cells. The overall structure of the cell was relatively complete, the boundary between the nucleus and the cytoplasm was

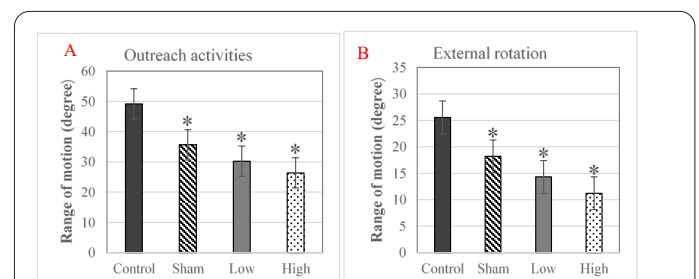


Fig. 1. Comparison of glenohumeral joint abduction and external rotation activity of rats in each group. (Note: * indicated significant difference compared with the control group ($p < 0.05$). Figure A was the glenohumeral joint abduction, and Figure B was the external rotation range).

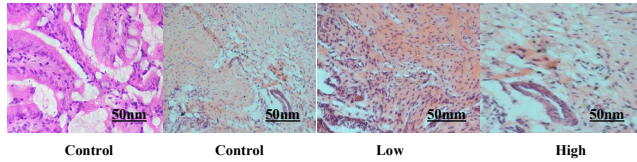


Fig. 2. HE staining results of synovium tissue of rats in each group.

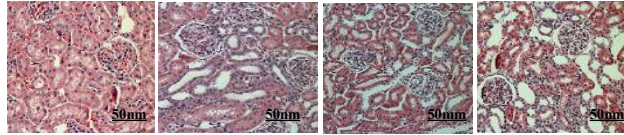


Fig. 3. HE staining results of vascular tissues of rats in each group.

clearly visible, and the overall shape of the nucleus was complete. In the Control group, the folds of the rat joint capsule synovium were not obvious, and the protrusions were obvious, but the groove between the protrusions and the protrusions was shallow, and the synovial area was reduced. Some inflammatory cell infiltration can be seen in the cells, and the overall organization of some cells was incomplete. The boundary between the nucleus and cytoplasm was blurred, and the nucleus morphology was partially changed. The pathological changes of Low group and High group were similar to those of Control group, but the degree had deepened and High group had the highest degree of lesion.

After HE staining, the blood vessels around the shoulder joints of each group of rats were observed under an optical microscope. The results are shown in Figure 3. The rat blood vessels in the Sham group showed no obvious changes. The endothelial tissue of the blood vessels was intact and smooth, the cell structure was clear and complete, the nucleus morphology was normal, and there was no overall enlargement or reduction of the cells, and there was no tendency for cell fibrosis. In the Control group, the cell membrane of rat vascular endothelial tissue showed obvious shrinkage and the overall cell morphology was incomplete. The nucleus was contracted, and the nucleolus gathered under the nucleus. Part of the granulation tissue appeared in the blood vessel, there was new angiogenesis and some cells showed the trend of fibrosis. The pathological changes of Low group and High group were similar to those of Control group, but the changes were more obvious, and High group had the highest degree of lesion.

3.3. Comparison of MMP14 gene expression in rats in each group

RT-PCR, Western blot and Immunohistochemical method and were used to detect the expression of MMP14 gene in each group of rats. RT-PCR results were shown in Figure 4A, Western blot results were shown in Figure 4B, and the immunohistochemical results were shown in Figure 4C. The results showed that compared with Sham group, MMP14 in Control group, Low group, and High group all increased significantly, and the difference was statistically significant ($P < 0.05$). In Control group, Low group, and High group, MMP14 gene expression in Low group and High group was higher than Control group, and MMP14 gene expression degree in High group was the highest.

3.4. Comparison of P-P38 MAPK gene expression in rats in each group

The results in Figure 5 show that compared with the Sham group, the p38 MAPK in the Control group, Low group, and High group all increased significantly, and the difference was statistically significant ($P < 0.05$). In Control group, Low group, and High group, p38 MAPK gene expression in Low group and High group was higher than Control group, and P-P38 MAPK gene expression in High group was the highest.

3.5. Comparison of VEGF gene expression in rats in each group

RT-PCR, Western blot and Immunohistochemical method and were used to detect the expression of VEGF gene in each group of rats. RT-PCR results were shown in Figure 6A, Western blot results were shown in Figure 6B, and the immunohistochemical results were shown in Figure 6C. The results showed that compared with Sham group, VEGF in Control group, Low group, and High group all increased significantly, and the difference was statistically significant ($P < 0.05$). In Control group, Low group, and High group, VEGF gene expression in Low group and High group was higher than Control group, among which VEGF gene expression in High group was the highest.

4. Discussion

Frozen shoulder refers to a shoulder joint disease first characterized by shoulder pain and joint movement. At present, the pathogenesis of frozen shoulder is still

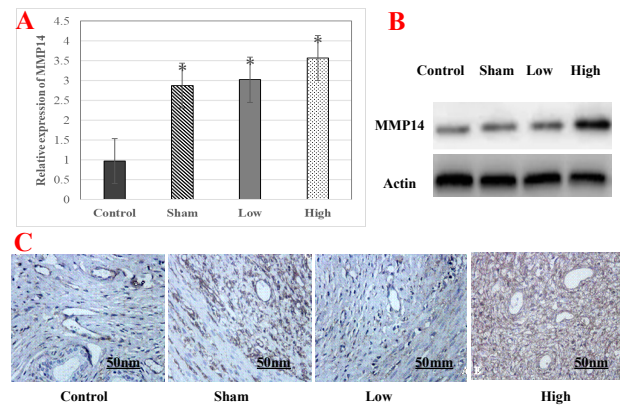


Fig. 4. MMP14 gene expression in each group under RT-PCR. (Note: * indicated a significant difference compared with the control group, $P < 0.05$. A: MMP14 gene expression; B: Western blot; C: HE result).

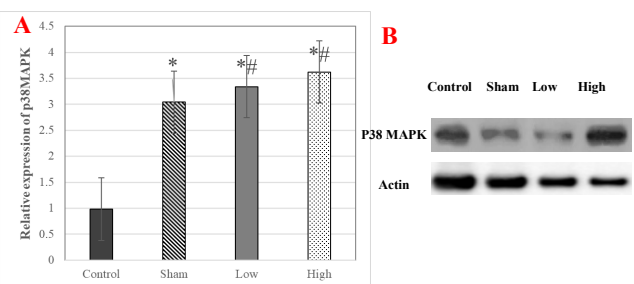
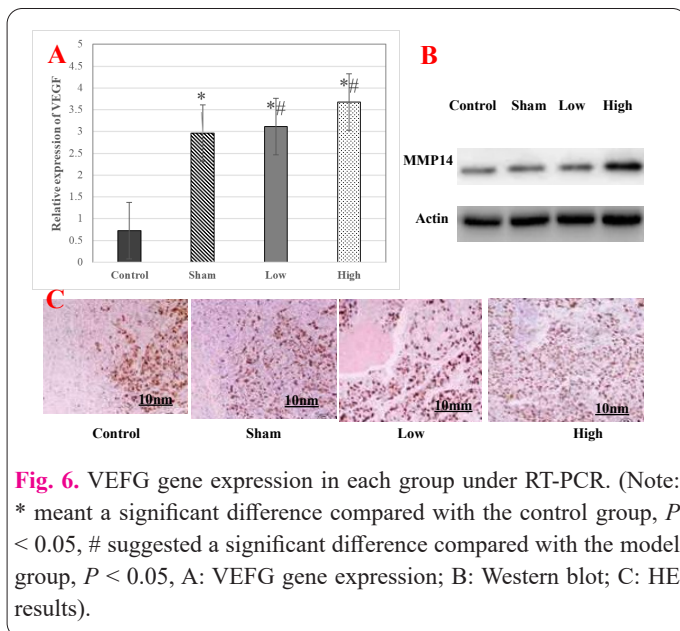


Fig. 5. The expression of p38 MAPK gene in each group. (Note: * meant a significant difference compared with the control group, $P < 0.05$; # meant a significant difference compared with the model group, $P < 0.05$. A: Gene expression; B: Western blot).



controversial, and many scholars believe that the pathological changes of frozen shoulder are mainly manifested as shoulder capsular contracture, thickening, chronic inflammation, and fibrosis [11]. Bunker et al. [12] found in patients with frozen shoulder that the joint capsule in the affected shoulder showed chronic fibrosis, and immunohistochemistry showed obvious fibroblast and myofibroblast proliferation in the primary frozen shoulder. Coracohumeral ligament is the main factor of significant external rotation of the shoulder and the primary focus of interfreezing. Omari et al. [13] believed that during the treatment of frozen shoulder, coracobrachial ligament thickened and contracted, with proliferative fibroblasts and myofibroblasts, and satisfactory results were achieved after the relaxation of coracobrachial ligament. In the study of Hwang et al. [14], it was concluded that at the present stage, the secondary frozen shoulder model is often constructed by surgical methods, that is, artificially traumatized the shoulder muscles of animals. This method is easy to construct but is different from the secondary frozen shoulder in human body. Atsuto et al. [15] fixed the glenohumeral joint of the rat with internal fixation and successfully built the shoulder contracture model. The changes in the joint capsule and synovium may play an important role in the occurrence of the contracture. Soslowsky et al. [16] and Soslowsky et al. [17] made animal models of chronic shoulder joint injury with excessive exercise, with a tilt Angle of 10 degrees and a speed of 17 m/min, one hour a day, five days a week. Kim et al. [18] constructed a rat model to analyze the influence of rotator cuff healing, and the carrier may have different effects on the early stage of rotator cuff healing. By summarizing the experience of previous studies, this experiment adopted the exercise method to construct the secondary frozen shoulder model in rats and adopted the load measurement of glenohumeral joint motion to quantify the success of the secondary frozen shoulder model. This method is closer to the cause of secondary shoulder freezing in most human bodies, and the measurement standard is more consistent with the normal movement of human body, and can effectively explain the pathological changes of the body.

Experimental results showed that synovium tissue of secondary frozen shoulder rats had obvious hyperplasia

and angiogenesis. In addition, in the group injected with transforming growth factor, the synovium and vascular increase in both low-dose and high-dose were stronger than those in the control group, indicating transforming growth factor promoted the proliferation of synovium and blood vessels to a certain extent, which was consistent with the clinical study of Lee et al. [19], who found that the transforming growth factor in patients with secondary frozen shoulder was significantly higher than that in normal people, which further illustrated the inseparable relationship between transforming growth factor, synovium, and vascular proliferation.

As a functional factor that plays an important role in extracellular matrix gene expression, matrix degradation, cell proliferation and differentiation, cell apoptosis, and immune regulation, the transforming factor also plays a role in promoting fibrosis [20]. Transforming growth factors can transform the phenotype of normal fibroblasts. In the presence of epidermal growth factor, fibroblast growth characteristics were changed to achieve growth in AGAR, and the inhibitory effect of density dependence in growth was lost. Studies have shown that growth factors can effectively inhibit the proliferation of polyclonal cells, and participate in various physiological processes such as the occurrence and development of tumors, immune response, wound repair, and the formation of intercellular interstitium. It is also an important regulatory factor in the process of cell fibrosis, which can promote the increase of extracellular matrix production, inhibit the decrease of collagen degradation of collagenase and matrix metalloproteinase, and promote the proliferation of stellate cells, resulting in the aggravation of fibrosis [21]. The experimental results showed that the expression of MMP-14, p38 MAPK, and VEGF in Control group, Low group, and High group was significantly higher than that of Sham group, and the expression of High group was the highest among the above three groups. This indicated that the high-dose group had the most serious shoulder joint fibrosis, synovial tissue hyperplasia and vascularization. Based on the results of this experiment, a reasonable assumption can be made that on the one hand, transforming growth factor promotes synovium tissue fibrosis by itself, and on the other hand promotes synovium tissue fibrosis by activating MMP-14. As an important channel of inflammatory response, p38 MAPK has an important connection with the body's frozen shoulder inflammation anyway [22-24]. The transforming growth factor aggravates the body's inflammatory response through its effects. Hammad et al. [25] confirmed in a study that adding transforming growth factors can aggravate the inflammatory response to a certain extent. VEGF, as a highly specific growth factor promoting endothelial cells in the learning tube, mainly induces angiogenesis in the body, promotes the degeneration of extracellular matrix and induces the migration and proliferation of vascular endothelial cells, which ultimately leads to new angiogenesis [26]. Experimental results showed that transforming growth factor can promote the increase of VEGF expression, which was the same as the results obtained by Pedersen et al. [27] in vitro cell induction. In this work, the synovial tissue of shoulder joint was obtained by making a frozen shoulder model, and the results showed that the expressions of MMP-14 and p38 MAPK-related genes increased in synovial tissue. This indicated fibroblastic synovial tissue hyperplasia and increased vascularization

in subacromial synovial tissue of patients with secondary frozen shoulder. It is also clear that the hyperplasia of acromial slide tissue and increased vasculature in patients with secondary frozen shoulder models is a major cause of shoulder fibrosis and shoulder limitation in patients.

5. Conclusion

In this experiment, a rat secondary frozen shoulder model was successfully constructed through exercise method, and the rats with the secondary frozen shoulder were evaluated by measuring the movement of the rat glenohumeral joint, the physiological changes of synovium tissue and vascular tissue, and the expression of MMP14, p38 MAPK, and VEGF to perform a more comprehensive assessment. Experimental results showed that synovium tissue proliferation and increased blood vessels are important causes of secondary frozen shoulder in rats, and transforming growth factors can promote synovial hyperplasia and increased blood vessels. The high expression of MMP-14, p38 MAPK, and VEGF is an important cause of synovial hyperplasia and increased blood vessels, and transforming growth factors can promote the high expression of these genes. This experiment innovatively used the exercise method to construct the rat secondary frozen shoulder model, which made the constructed model closer to the body characterization, thus revealing the effect of transforming growth factor on synovium tissue and vascular tissue-related genes in the secondary frozen shoulder, which has laid a certain foundation for clinical treatment of secondary frozen shoulder. However, the sample size in this experiment was small. Because a new method was used to construct the model, the method needs to be further quantified.

Conflict of Interests

The author has no conflicts with any step of the article preparation.

Consent for publications

The author read and approved the final manuscript for publication.

Ethics approval and consent to participate

This study was approved by the Ethics Committee for the Use of Experimental Animals of Hebei Medical University (approval no. Z2019-012-1; Hebei, China).

Informed Consent

The authors declare not used any patients in this research.

Availability of data and material

The data that support the findings of this study are available from the corresponding author upon reasonable request.

Authors' contributions

Jie Xu and Pengcheng Wang designed the study and performed the experiments, Dong Ren and Fei Liu collected the data, Dong Ren, Fei Liu and Shuren Liu analyzed the data, Jie Xu and Pengcheng Wang prepared the manuscript. All authors read and approved the final manuscript.

Funding

The Natural Science Foundation of Hebei Province (Shijiazhuang, China).

References

- Itoi E, Arce G, Bain GI, Diercks RL, Guttman D, Imhoff AB et al (2016) Shoulder Stiffness: Current Concepts and Concerns. *Arthroscopy* 32:1402-1414. doi: 10.1016/j.arthro.2016.03.024
- Zreik NH, Malik RA, Charalambous CP (2016) Adhesive capsulitis of the shoulder and diabetes: a meta-analysis of prevalence. *Mltj-Muscle Ligament* 6:26-34. doi: 10.11138/mltj/2016.6.1.026
- Miyazaki AN, Santos PD, Silva LA, Sella GD, Carrenho L, Checchia SL (2017) Clinical evaluation of arthroscopic treatment of shoulder adhesive capsulitis. *Rev Bras Ortop* 52:61-68. doi: 10.1016/j.rboe.2016.12.004
- Asheghan M, Aghda AK, Hashemi E, Hollisaz M (2016) INVESTIGATION OF THE EFFECTIVENESS OF ACUPUNCTURE IN THE TREATMENT OF FROZEN SHOULDER. *Mater Socio-med* 28:253-257. doi: 10.5455/msm.2016.28.253-257
- Wang J, Guo L, Shen D, Xu X, Wang J, Han S et al (2017) The Role of c-SKI in Regulation of TGFbeta-Induced Human Cardiac Fibroblast Proliferation and ECM Protein Expression. *J Cell Biochem* 118:1911-1920. doi: 10.1002/jcb.25935
- Xue M, Gong S, Dai J, Chen G, Hu J (2016) The Treatment of Fibrosis of Joint Synovium and Frozen Shoulder by Smad4 Gene Silencing in Rats. *Plos One* 11:e0158093. doi: 10.1371/journal.pone.0158093
- Wermuth PJ, Carney KR, Mendoza FA, Piera-Velazquez S, Jimenez SA (2017) Endothelial cell-specific activation of transforming growth factor-beta signaling in mice induces cutaneous, visceral, and microvascular fibrosis. *Lab Invest* 97:806-818. doi: 10.1038/labinvest.2017.23
- Shevchenko AV, Kononkov VI, Korolev MA, Ubshaeva YB, Prokofiev VF (2015) [Matrix metalloproteinase 2, 3, and 9 gene polymorphisms in women with rheumatoid arthritis]. *Terapevt Arkh* 87:36-40. doi: 10.17116/terarkh2015871236-40
- Qin S, Wang F, Zhou M, Ding W, Chen L, Lu Y (2015) Immunolocalization of membrane-type 1 MMP in human rheumatoid synovium tissues. *Int J Clin Exp Pathol* 8:9286-9292.
- Kanno A, Sano H, Itoi E (2010) Development of a shoulder contracture model in rats. *J Shoulder Elb Surg* 19:700-708. doi: 10.1016/j.jse.2010.02.004
- Kim DH, Lee KH, Lho YM, Ha E, Hwang I, Song KS et al (2016) Characterization of a frozen shoulder model using immobilization in rats. *J Orthop Surg Res* 11:160. doi: 10.1186/s13018-016-0493-8
- Bunker TD, Anthony PP (1995) The pathology of frozen shoulder. A Dupuytren-like disease. *J Bone Joint Surg Br* 77:677-683.
- Omari A, Bunker TD (2001) Open surgical release for frozen shoulder: surgical findings and results of the release. *J Shoulder Elb Surg* 10:353-357. doi: 10.1067/mse.2001.115986
- Horst R, Maicki T, Trabka R, Albrecht S, Schmidt K, Metel S et al (2017) Activity- vs. structural-oriented treatment approach for frozen shoulder: a randomized controlled trial. *Clin Rehabil* 31:686-695. doi: 10.1177/0269215516687613
- Kanno A, Sano H, Itoi E (2010) Development of a shoulder contracture model in rats. *J Shoulder Elb Surg* 19:700-708. doi: 10.1016/j.jse.2010.02.004
- Soslowky LJ, Thomopoulos S, Tun S, Flanagan CL, Keefer CC, Mastaw J et al (2000) Neer Award 1999. Overuse activity injures the supraspinatus tendon in an animal model: a histologic and biomechanical study. *J Shoulder Elb Surg* 9:79-84.
- Soslowky LJ, Carpenter JE, DeBano CM, Banerji I, Moalli MR (1996) Development and use of an animal model for investigations on rotator cuff disease. *J Shoulder Elb Surg* 5:383-392. doi: 10.1016/s1058-2746(96)80070-x
- Kim SY, Chae SW, Lee J (2014) Effect of Poloxamer 407 as a car-

- rier vehicle on rotator cuff healing in a rat model. *J Orthop Surg Res* 9:12. doi: 10.1186/1749-799X-9-12
19. Cohen C, Leal MF, Loyola LC, Santos S, Ribeiro-Dos-Santos A, Belangero PS et al (2019) Genetic variants involved in extracellular matrix homeostasis play a role in the susceptibility to frozen shoulder: A case-control study. *J Orthop Res* 37:948-956. doi: 10.1002/jor.24228
20. Yang R, Deng H, Hou J, Li W, Zhang C, Yu M et al (2020) Investigation of salmon calcitonin in regulating fibrosis-related molecule production and cell-substrate adhesion in frozen shoulder synovial/capsular fibroblasts. *J Orthop Res* 38:1375-1385. doi: 10.1002/jor.24571
21. Guo T, Han J, Yuan C, Liu J, Niu C, Lu Z et al (2020) Comparative proteomics reveals genetic mechanisms underlying secondary hair follicle development in fine wool sheep during the fetal stage. *J Proteomics* 223:103827. doi: 10.1016/j.jprot.2020.103827
22. Alhashimi R (2018) Analytical Observational Study of Frozen Shoulder among Patients with Diabetes Mellitus. *Joints* 6:141-144. doi: 10.1055/s-0038-1676105
23. Cho CH, Kim DH, Bae KC, Lee D, Kim K (2016) Proper site of corticosteroid injection for the treatment of idiopathic frozen shoulder: Results from a randomized trial. *Joint Bone Spine* 83:324-329. doi: 10.1016/j.jbspin.2015.06.014
24. Cher J, Akbar M, Kitson S, Crowe L, Garcia-Melchor E, Hannah SC et al (2018) Alarmins in Frozen Shoulder: A Molecular Association Between Inflammation and Pain. *Am J Sport Med* 46:671-678. doi: 10.1177/0363546517741127
25. Hammad SM, Arsh A, Iqbal M, Khan W, Shah A (2019) Comparing the effectiveness of kaltenborn mobilization with thermotherapy versus kaltenborn mobilization alone in patients with frozen shoulder [adhesive capsulitis]: A randomized control trial. *J Pak Med Assoc* 69:1421-1424.
26. Rae GC, Clark J, Wright M, Chesterton P (2020) The effectiveness of hydrodistension and physiotherapy following previously failed conservative management of frozen shoulder in a UK primary care centre. *Musculoskelet Care* 18:37-45. doi: 10.1002/msc.1438
27. Pedersen AB, Horvath-Puho E, Ehrenstein V, Rorth M, Sorensen HT (2017) Frozen shoulder and risk of cancer: a population-based cohort study. *Brit J Cancer* 117:144-147. doi: 10.1038/bjc.2017.146