



Original Article



## Protective role of vitamin B6 on some histological changes in the liver and kidneys and measure some indicators of oxidation balance in male rats

Loay H. Ali<sup>1\*</sup>, Sara Hameed Rajab<sup>2</sup>, Eman Naji Saleh<sup>1</sup><sup>1</sup> Biology Department, College of Education for Pure Sciences, University of Anbar, Iraq<sup>2</sup> College of Pharmacy, University of Al Maarif, Al Anbar, 31001, Iraq

### Article Info

### Abstract



#### Article history:

Received: August 24, 2024

Accepted: November 08, 2024

Published: November 30, 2024

Use your device to scan and read the article online



This study aimed to evaluate the therapeutic effects of B6 in rats experimentally intoxicated by benzopyrene. Twenty-eight Male Sprague Dawley (white Swiss) rats weighing 170-210 g and 3-4 months old were utilized in this examination. Rats were divided into 4 control groups (G1), B[a]P 2 pmol/μL (G2), B6 only once per 2 days for a full month at 1000 mcg (15 dose per month) (G3), B6 + B[a]P (G4). The results showed an increase in the level of MDA and a significant decrease in the level of GSH in the second group compared to the negative control group, while no significant differences appeared in the third group, while a significant decrease in the level of MDA and a significant increase in the level of GSH were observed in the fourth group when compared with The second group. Hepatic and renal tissues were taken for histopathological study. The results showed that liver and kidney of G1 and G3 exhibit normal architecture. Liver of G2 revealed blood congestion in certain sinusoids and atrophied hepatocytes, there was also hyperplasia of Kupffer cells in the pockets of blood sinusoids, while renal tissues showed inflammatory cell infiltration, mesangial cell hyperplasia, and blood vessel congestion and bleeding. In contrast liver and kidney tissues in G4 showed mild lesion after B6 treatment. In conclusion, Pyridoxin (B6) can alleviate the hepatic and renal tissues damaged caused by benzopyrene.

**Keywords:** Benzopyrene, B6, liver, Kidney

### 1. Introduction

A polyaromatic hydrocarbon known as benzo[a]pyrene (B[a]P) is created when organic matter, such as waste and decomposing plants, is not completely burned [1]. Moreover, tobacco smoke, especially cigarette smoke, contains it [2,3]. Exposure to B[a]P results in structural and physiological alterations in the lungs, including emphysema, inflammation, edema, and surfactant dysfunction, which might pave the way for the emergence of a number of chronic illnesses of lung [2-6]. Short term B[a]P exposure has been utilized to determine harmful lung effects and established as a toxicant model to investigate harmful impacts on the respiratory system [7,8].

Management of oxidative stress and toxicity due to chemical toxicity is greatly aided by chemicals and various pharmacologically active substances found in food, vegetables, and medicinal plants [9-12]. Fruits and vegetables are a common source of flavonoids, which are phenolic chemicals that are part of the human diet. They demonstrate antioxidant, anti-inflammatory, anti-mutagenic, anti-carcinogenic, and enzymatic activity modulation properties [13-15].

Chemical toxicants injure tissue through a variety of

methods, many of which activate pathways that contribute to oxidative stress and cell survival and apoptosis [16]. Cytochrome P450 1A1 (CYP1A1) metabolizes B[a]P to epoxide, which attaches to DNA to create an adduct. ROS are produced during this process and cause inflammation and oxidative stress, which in turn damages cell components such as lipids, membranes, and proteins [17-19].

Another approach to chelation treatment might be antioxidant supplements, as free radicals were thought to be produced during the pathogenetic processes caused by lead exposure [20]. It has been shown that vitamins, especially B, C, and E, play a crucial role in combating the toxicological symptoms of lead poisoning. These vitamins may restore the pro/antioxidant balance and chelate lead from tissues [21].

Pyridoxine, or vitamin B6, is a crucial cofactor in the metabolic trans-sulfuration process, which converts dietary methionine into cysteine. Vit. B6 is a mild chelator and an antioxidant because it increases glutathione (GSH) synthesis [22,23]. One study found that giving lead-exposed rat's pyridoxine as a supplement increased their ALAD activity and decreased their blood, liver, and kidney lead levels [24]. Anecdotal evidence suggests that vita-

\* Corresponding author.

E-mail address: [hatemloay81@uoanbar.edu.iq](mailto:hatemloay81@uoanbar.edu.iq) (L. H. Ali).Doi: <http://dx.doi.org/10.14715/cmb/2024.70.11.23>

min B1 (thiamine) may mitigate the acute symptoms of lead poisoning. According to previous research [25- 27].

## 2. Materials and methods

Twenty-eight Male Sprague Dawley rats weighing 170-210 g and aged 12-16 weeks were used in this investigation. The study was conducted on June 1 for two months, the animals were placed in the animal house of the Biology Department at the College of Education for Pure Sciences-University of Anbar, and rats were housed in plastic cages measuring 15x20x30 cm with metal covers specifically made for this purpose. In a controlled environment, the animals spent 11 hours in the light and 13 hours in the dark. The constant temperature was 22±2 degrees Celsius. They were given two weeks to adjust to their new environment and be sure they weren't sick, during which time they were cleaned and Sterilized weekly.

### 2.1. Experimental design

Rats were classified into four groups at random and each group contained 7 animals : (G1) control receiving standard diet and water ad libitum, (G2) exposed to B[a]P 2 pmol/μL, (G3) treated with B6 only once per 2 days for a full month at 1000 mcg (15 dose per month), and (G4) B6 + B[a]P treated via oral gavage once per 2 days for a full month at 1000 mcg (15 dose per month) and then exposed to B[a]P for two weeks.

For the experimental groups, the chemical benzo-pyrene (B[a]P) was produced as an oral gavage stock by dissolving pharmaceutical-grade olive oil to the appropriate concentration in high-purity benzopyrene powder, which was sourced from a certified third-party company. The solution was ensured to be stable and devoid of contaminants by preparing it in low-light conditions, stirring it with a magnetic stirrer, pouring it into amber glass vials, and storing it at -20°C until needed. We had enough stability till we could utilize it since the solution had 2 pmol/μL B[a]P. These techniques are now standard operating procedures for making experimental solutions. This is the key to understanding the fate of environmental contaminants that defy conventional chemical analysis. For oral delivery, the dosage of B[a]P solution was frozen at 4 °C overnight and then brought to room temperature before future administration; this process was repeated every other day for a total of 10 administrations in each rat. Careful attention to dosage accuracy and aseptic technique during feeding operations allowed all exposed and treated groups to demonstrate consistent results after each administration of thawed B[a]P solution into the stomachs of rats.

### 2.3. Study of the level of antioxidants/oxidants

Test for lipid peroxide Malondialdehyde (MDA) levels in serum were measured using the method described in the attached working method, while glutathione is determined by assay GSH kit.

### 2.4. Histopathological study

We performed histological investigations on liver, kidney, and brain tissues that were removed after the rats were euthanized. The tissues were then washed in ice-cold saline. The livers and kidneys of the dissected rats were fixed in 10% formalin after dissection. After that, they were immersed in xylene to thin them down, processed through an ethanol solution in phases, and finally embedded in

paraffin cubes. Subsequently, a compound light microscope equipped with a digital camera was used to analyze thin slices (5 μm) that were stained with hematoxylin and eosin solution.

### 2.5. Statistical analysis

Under the SPSS and Microsoft Excel XP systems, data were statistically analyzed using the Minitab statistical tool. The Range Duncan's Multiple tests were used to compare the means of the data. Values less than 0.05 were deemed statistically significant, but probability levels greater than 0.05 were regarded as non-significant:  $P < 0.05$  significant.

## 3. Results

The results in the second positive group treated with benzo pyrene showed a significant increase ( $P \leq 0.05$ ) in the level of MDA with a decrease in the level of the antioxidant GSH when compared with the negative control group. While the results did not record any significant difference in the level of the above measurements in the third group that was treated with Vit. B6, whereas the fourth group's MDA level significantly decreased ( $P \leq 0.05$ ), the findings of our current investigation that was treated with vit. B6 with benzo pyrene, In addition, there was a significant increase in GSH levels (Figures 1 and 2).

Histological Sections of kidney and liver samples from different groups provided light on benzopyrene's side effects and B6's possible therapeutic function in this inves-

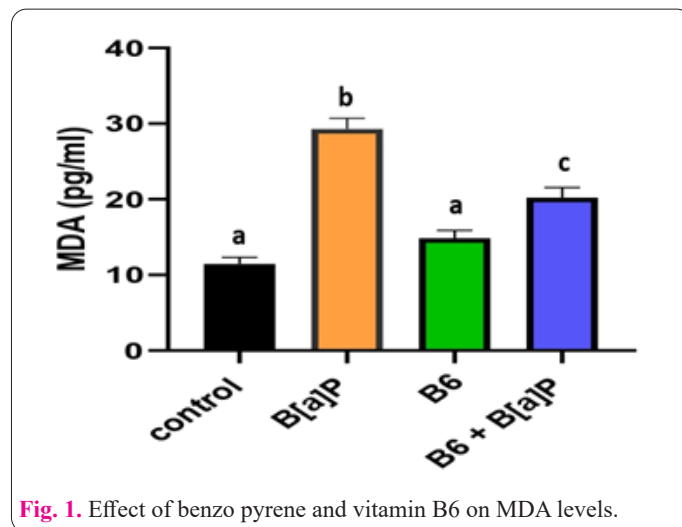


Fig. 1. Effect of benzo pyrene and vitamin B6 on MDA levels.

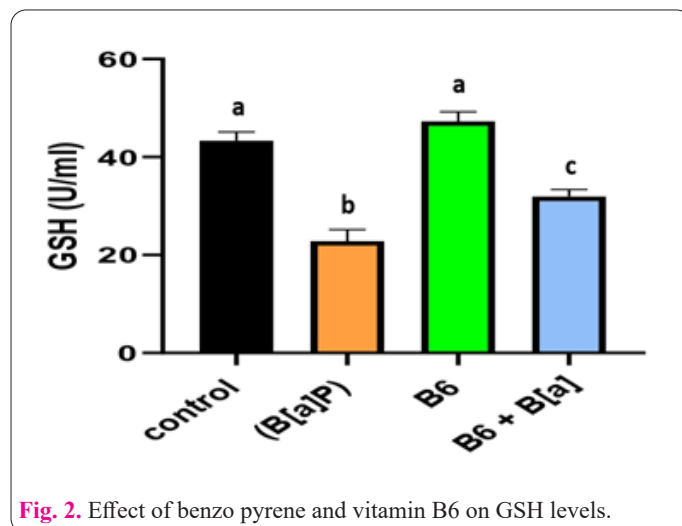
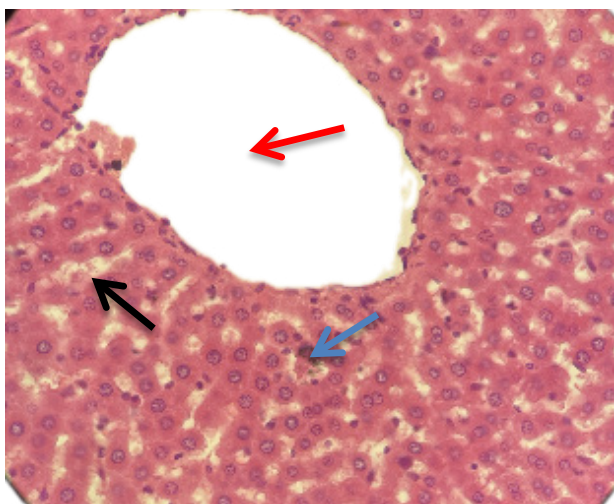


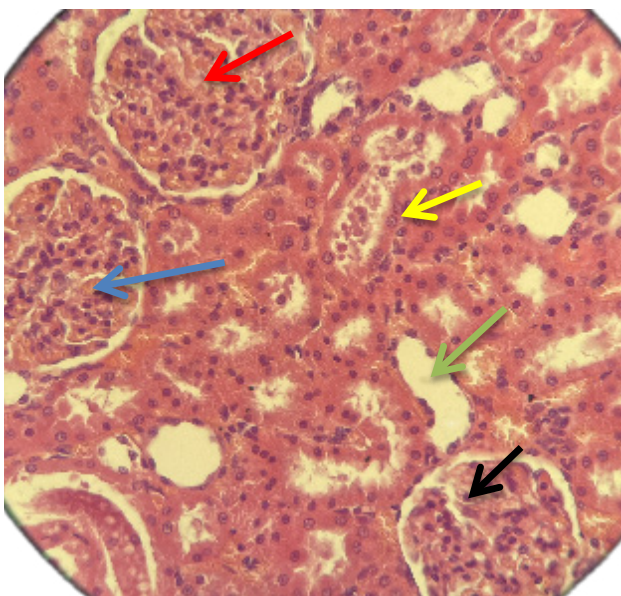
Fig. 2. Effect of benzo pyrene and vitamin B6 on GSH levels.

tigation. The G1 control group's liver tissue had normal architecture. (Fig 3), The histological examination of the control group's renal tissue revealed typical features, such as lobulated glomeruli, Bowman's capsule, the capsular space, and convoluted tubules at the proximal and distal ends. (Fig. 4). There were noticeable structural alterations in the liver tissue of the group that was treated with benzopyrene (G2). Where there was blood congestion in certain sinusoids and atrophied hepatocytes, there was also hyperplasia of Kupffer cells in the pockets of blood sinusoids (Fig. 5). In contrast, the kidney tissue of the group that was administered benzopyrene showed significant histological alterations, including inflammatory cell infiltration, mesangial cell hyperplasia, and blood vessel congestion and bleeding (Fig. 6).

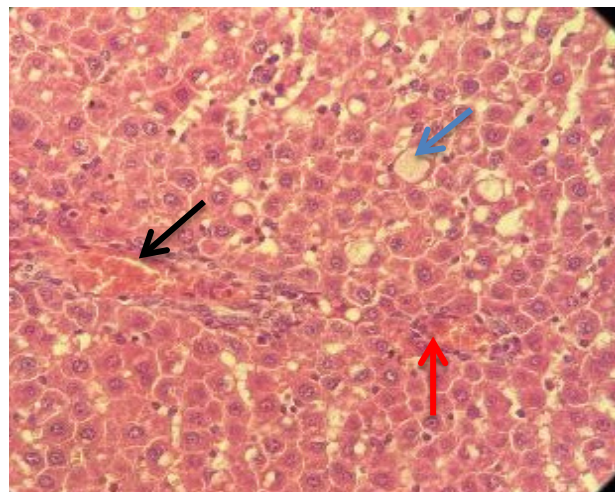
The liver and kidney tissues of B6 group (G3) shows



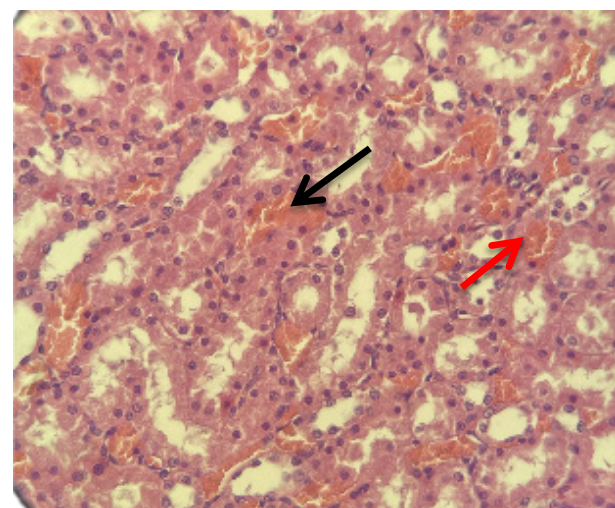
**Fig. 3.** Liver tissue: In the liver control group with normal liver tissue, the central vein is observed to have a wide lumen and is lined with simple squamous cells. The rows of polygonal hepatocytes are clearly noted, along with the hepatic sinusoids containing Kupffer cells. (H and E X40).



**Fig. 4.** Kidney tissue. The kidney tissue is normal, featuring lobulated glomeruli (Red arrow), the capsular space (Blue arrow), Bowman's capsule (Green arrow), proximal convoluted tubules (Yellow arrow), and distal convoluted tubules (Black arrow) (H and E X40).



**Fig. 5.** The Liver of rats of G2(toxin group) shows blood vessels congestion (Black arrow), fatty changes (Blue arrow)and inflammatory cells infiltration (Red arrow) (Hand E X40).

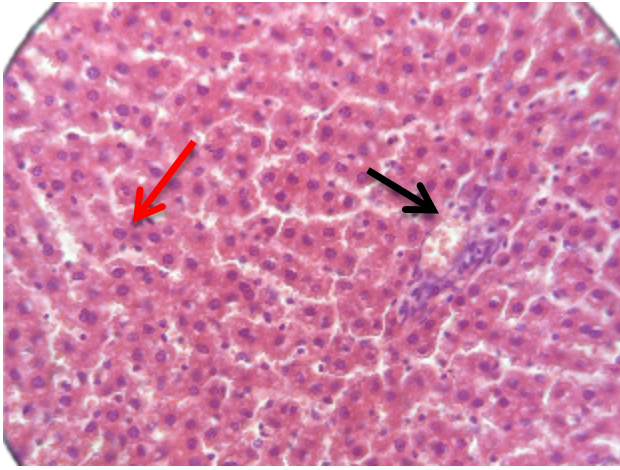


**Fig. 6.** Kidney from the rat of G2(toxin group) shows blood vessel congestion and hemorrhage (Black arrow), Mesangial cell hyperplasia and inflammatory cell infiltration(Red arrow). (Hand E X40).

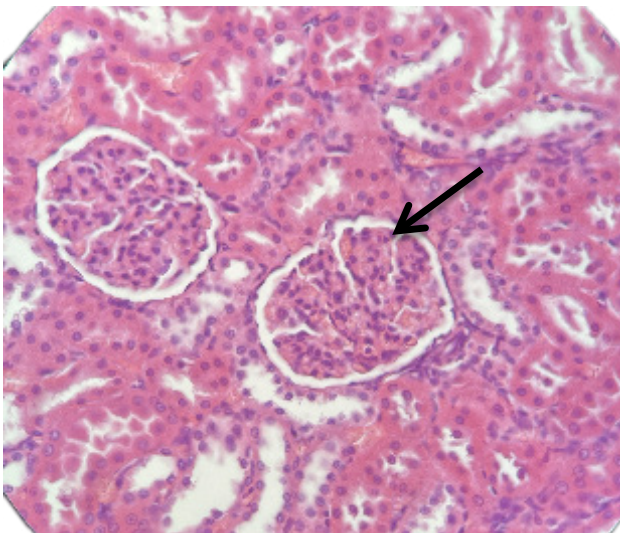
normal histology (Figures 7 and 8). Liver from rat of G4 shows blood vessels congestion, fatty changes and inflammatory cells infiltrating with enhancement when compared with G2 (Fig. 9). While the renal tissues show mild glomerular atrophy and vacuoles (Fig. 10).

#### 4. Discussion

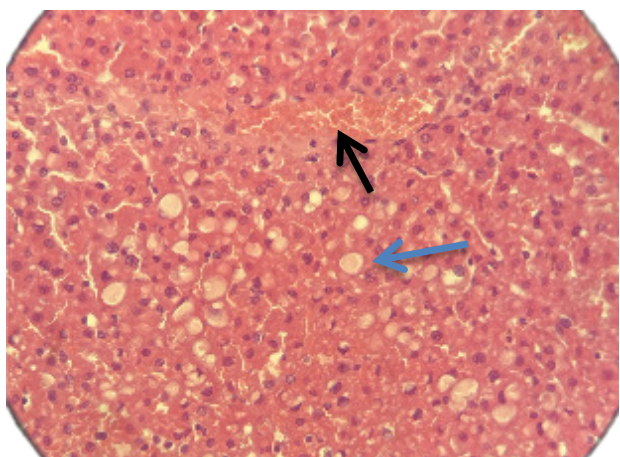
Based on our search, no prior research has examined the use of B6 to treat rats exposed to benzopyrene toxicity. The results of this study found a significant reduction in the level of (GSH) in adult male white rats treated with benzo pyrene at a concentration (2 pmol/ $\mu$ L) of body weight compared to the control group. The reason for the decrease in the level of glutathione may be attributed to the occurrence of a state of oxidative stress as a result of continuous treatment with benzo pyrene and as a result of the effective participation of glutathione in Preventing oxidative stress in the event of oxidative stress, either through direct removal of free radicals or through enzymes that are an essential substance, such as glutathione peroxidase, which leads to increased consumption of glutathione and its transformation into its inactive form, glutathione di-



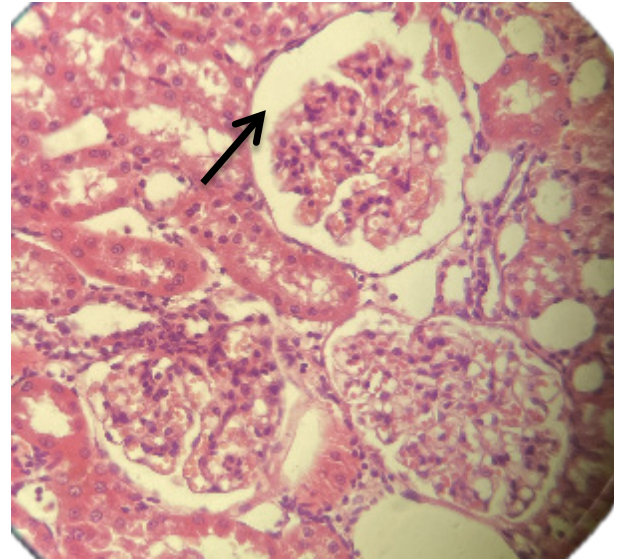
**Fig. 7.** Liver from a rat of G3 normal histology shows hepatocytes (Red arrow) and a branch of the portal vein (Black arrow).



**Fig. 8.** The kidney from the rat of G3 normal histology shows featuring lobulated glomeruli (Black arrow).



**Fig. 9.** Liver from the rat of G4(toxin+B6) shows mild blood vessels congestion (Black arrow), and fatty changes(Blue arrow) (Hand E X40).



**Fig. 10.** kidney from a rat of G4 shows mild glomerular atrophy and vacuoles (Black arrow) (Hand E X40).

of the enzyme actyl-COA - which is an important part in the metabolic processes and the direct oxidation of fatty acids that leads to an increase in the production of hydrogen peroxide,  $H_2O_2$  that contributes to the production of fat peroxidation, as benzo pyrene poisoning causes an increase in the rate of fat peroxidation and a loss of the integrity of cellular membranes[29].

While no changes were recorded in the two indicators above in the third group that was given vitamin B6, this indicates that this vitamin has a positive effect and has no harm to the body in the dose that was given, While it gave the best results in the fourth group, this may be attributed to the positive effect of the vitamin B6, which is one of the important vitamins involved in many important biological activities, especially food metabolism, It also enhances the immune system by increasing the efficiency of the production of antioxidants, which in turn work as scavengers of free radicals resulted from benzo pyrene. Thus reducing the level of these radicals and, as a final result, reducing the peroxidation of fats (MDA).

As for histological changes, consistent with other published studies on the hepatotoxic effects of benzopyrene, they show that benzopyrene severely disrupts the normal architecture of liver cells [30]. These results corroborate earlier reports that benzopyrene is a nephrotoxicant and may cause kidney damage via apoptotic and necrotic effects [31].

Vitamin B6 is a mild chelator and an antioxidant because it increases glutathione (GSH) synthesis, at normal doses it doesn't affect hepatic and renal tissues [23]. Therefore, this study aims to be the first to assess the therapeutic effects of B6 in these rats. It has been observed that supplementing lead-exposed rats with pyridoxine improves Delta-aminolevulinic acid dehydratase (ALAD) activity and lowers lead levels in the rats' blood, liver, and kidneys [24]. The metabolic trans-sulfuration route is the proposed mechanism by which pyridoxine mediates benzopyrene toxicity. This process enables the metabolism of cysteine from methionine, the primary food supply of cysteine and the rate-limiting amino acid in GSH formation [32]. In addition to its modest chelating and antioxidant properties, vitamin B6 stimulates the synthesis of glutathione (GSH) [23]. The ring in the nitrogen molecule or vitamin B6's

mercaptopropanol[28].

The results also showed an increase in the level of lipid peroxidation (MDA), The reason for the increase in lipid peroxidation (MDA) is due to treatment with benzo pyrene because of its effect on stimulating the attachment

criss-cross with benzopyrene absorption are two possible explanations for why it chelates the compound. When comparing rats exposed to toxicants and those with diet-induced vitamin B6 deficits to rats exposed to lead and those with normal vitamin B6 levels [33] found that the glutathione levels of the former group were much lower.

## 5. Conclusion

The findings of this study suggest that pyridoxine (B6) plays a significant role in mitigating the adverse effects of benzopyrene (B[a]P) toxicity on hepatic and renal tissues in rats. The data indicate that while B[a]P exposure leads to increased levels of malondialdehyde (MDA) and decreased levels of glutathione (GSH), the administration of B6 effectively normalizes these parameters, indicating its protective antioxidant properties. Histopathological analyses further corroborate these results, showing that B6 treatment resulted in only mild lesions in liver and kidney tissues compared to the more severe damage observed in the B[a]P-only group. Therefore, this study underscores the potential therapeutic application of vitamin B6 in counteracting oxidative stress and tissue damage induced by environmental toxins such as benzopyrene, warranting further investigation into its mechanisms and broader implications for toxicology and public health.

## References

- Rengarajan T, Rajendran P, Nandakumar N, et al. (2015). Exposure to polycyclic aromatic hydrocarbons with special focus on cancer. *Asian Pac J Trop Biomed* 5(3): 182–189. doi:10.1016/S2221-1691(15)30003-4
- Jahangir T, Sultana S. (2008). Benzo(a)pyrene induced genotoxicity: attenuation by farnesol in a mouse model. *J Enzyme Inhib Med Chem* 23(6): 888–894. doi: 10.1080/14756360701448768
- Yeo CD, Kim JW, Ha JH, et al. (2014). Chemopreventive effect of phosphodiesterase-4 inhibition in benzo(a)pyrene induced murine lung cancer model. *Exp Lung Res* 40(10): 500–506. doi: 10.3109/01902148.2014.950769
- Young RP, Hopkins RJ, Christmas T, et al. (2009) COPD prevalence is increased in lung cancer, independent of age, sex and smoking history. *Eur Respir J* 34(2): 380–386. doi: 10.1183/09031936.00144208
- Qamar W, Sultana S (2008) Farnesol ameliorates massive inflammation, oxidative stress and lung injury induced by intratracheal instillation of cigarette smoke extract in rats: an initial step in lung chemoprevention. *Chem Biol Interact* 176(2–3): 79–87.
- Qamar W, Khan AQ, Khan R (2012) Benzo(a)pyrene induced pulmonary inflammation, edema, surfactant dysfunction, and injuries in rats: alleviation by farnesol. *Exp Lung Res* 38(1): 19–27.
- Ravichandiran V, Ahamed HN, Nirmala S (2011) Natural flavonoids and lung cancer. *Int J Comp Pharm* 2(6): 1–9.
- Tsao AS, Edward SK, Hong WK (2004) Chemoprevention of cancer. *CA Cancer J Clin* 54(3): 150–180.
- Amin AR, Kucuk O, Khuri FR, et al. (2009) Perspectives for cancer prevention with natural compounds. *J Clin Oncol* 27(16): 2712–2725.
- Das K, Tiwari RKS and Shrivastava DK (2010) Techniques for evaluation of medicinal plant products as antimicrobial agent: current methods and future trends. *J Med Plants Res* 4(2): 104–111.
- Pezzuto JM (1997) Plant-derived anticancer agents. *Biochem Pharmacol* 53(2): 121–133.
- Thakur VS, Deb G, Babcook MA, et al. (2014). Plant phytochemicals as epigenetic modulators: role in cancer chemoprevention. *AAPS* 16(1): 151–163.
- Birt DF, Hendrich S, Wang W (2001). Dietary agents in cancer prevention: flavonoids and isoflavonoids. *Pharmacol Ther* 90(2–3): 157–177.
- Galati G, Teng S, Moridani MY, et al. (2000). Cancer chemoprevention and apoptosis mechanisms induced by dietary polyphenolics. *Drug Metabol Drug Interact* 17(3–4): 311–349.
- Tripoli E, Guardia ML, Giammanco S, et al. (2007) Citrus flavonoids: molecular structure, biological activity and nutritional properties: a review. *Food Chem* 104(2): 466–479.
- Roberts RA, Laskin DL, Smith CV, et al. (2009) Nitrate and oxidative stress in toxicology and disease. *Toxicol Sci* 112(1): 4–16.
- Miller KP and Ramos KS (2001) Impact of cellular metabolism on the biological effects of benzo[a]pyrene and related hydrocarbons. *Drug Metab Rev* 33(1): 1–35.
- Patri M, Padmini A and Babu PP (2009) Polycyclic aromatic hydrocarbons in air and their neurotoxic potency in association with oxidative stress: a brief perspective. *Ann Neurosci* 16(1): 1–9.
- Veskoukias AS, Tsatsakis AM and Kouretas D (2012) Dietary oxidative stress and antioxidant defense with an emphasis on plant extract administration. *Cell Stress Chaperones* 17(1): 11–21.
- Flora SJS, Pande M, Mehta A (2003) Beneficial effect of combined administration of some naturally occurring antioxidants (vitamins) and thiolchelators in the treatment of chronic lead intoxication. *Chem Biol Interact* 145: 267–280.
- Patra RC, Swarup D, Dwivedi SK (2001) Antioxidant effects of  $\alpha$  tocopherol, ascorbic acid and l-methionine on lead induced oxidative stress to the liver, kidney and brain in rats. *Toxicol* 162: 81–88.
- Hsu PC, Hsu CC, Liu MY (1998) Lead-induced changes in spermatozoa function and metabolism. *Journal of Toxicology and Environmental Health, Part A* 55: 45–64.
- Guidotti TL, McNamara J, Moses MS (2008) The interpretation of trace element analysis in body fluids. *Indian J Med Res* 128: 524–532.
- Tandon SK, Flora SJS, Singh S (1987) Influence of pyridoxine (vitamin B6) on lead intoxication in rats. *Industrial Health* 25: 93–96.
- Flora SJ, Sharma RP (1986) Influence of dietary supplementation with thiamine on lead intoxication in rats. *Biol Trace Elem Res* 10: 137–144.
- Senapati SK, Dey S, Dwivedi SK, Patra RC, Swarup D (2000) Effect of thiamine hydrochloride on lead induced lipid peroxidation in rat liver and kidney. *Vet Hum Toxicol* 42: 236–237.
- Flora SJS. Nutritional components modify metal absorption, toxic response and chelation therapy. *J Nutr Environ Med* 2002;12: 53–67.
- Al-Asmari AK, Athar MT, Al-Shahrani HM, Al-Dakheel SI, Al-Ghamdi MA (2015) Efficacy of *Lepidium sativum* against carbon tetra chloride induced hepatotoxicity and determination of its bioactive compounds by GC-MS. *Toxicol Rep* 2:1319–1326. doi: 10.1016/j.toxrep.2015.09.006.
- Kakimoto PA, Tamaki FK, Cardoso AR, Marana SR, Kowaltowski AJ (2015) H<sub>2</sub>O<sub>2</sub> release from the very long chain acyl-CoA dehydrogenase. *Redox Biol* 4:375–80. doi: 10.1016/j.redox.2015.02.003.
- Kolade OY, Oladiji TA (2018) Protective effects of curcumin against benzopyrene induced liver toxicity in albino rats. In IOP Conference Series: Earth and Environmental Science (Vol. 210, p. 012013). IOP Publishing.
- Sello A, Eldemery M (2016) The potential preventive effects of turmeric (*Curcuma longa*) rhizomes against hepatotoxicity in rats induced by benzo [a] pyrene. *J Home Economics* 26(1):1–22.

32. Lyn P (2006). Lead toxicity part II: the role of free radical damage and the use of antioxidants in the pathology and treatment of lead toxicity. *Altern Med Rev* 11: 114-127. doi: 10.21426/B634143807
33. McGowan C (1989) Influence of vitamin B6 status on aspects of lead poisoning in rats. *Toxicol Lett* 47: 87-93. doi: 10.1016/0378-4274(89)90088-x