

Original Research

The effect of glycyrrhizic acid on traumatic spinal cord injury in rats

M. H. Sehitoglu^{1*}, M. Guven², Y. Yüksel³, T. Akman², A. Bozkurt Aras², A. A. Farooqi⁴, M. Cosar²

¹ Department of Medical Biochemistry, Faculty of Medicine, Canakkale Onsekiz Mart University, Canakkale, Turkey

² Department of Neurosurgery, Faculty of Medicine, Canakkale Onsekiz Mart University, Canakkale, Turkey

³ Department of Histology & Embryology, Faculty of Medicine, Afyon Kocatepe University, Afyon, Turkey

⁴ Laboratory for Translational Oncology and Personalized Medicine, Rashid Latif Medical College, Lahora, Pakistan

Abstract: Spine injury associated with traumatic spinal cord injury eventuates in oxidative stress, inflammation and neuronal apoptosis. The aim of this study is to find out whether the glycyrrhizic acid treatment protects spinal cord from traumatic injuries in rats. To this end, the rats were divided into three groups: group I; control group (no drug or operation, n=8), group II; traumatic spinal cord injury group (TSCI, n=8) and group III; glycyrrhizic acid group (TSCI-GA, 80 mg/kg, n=8). Total laminectomy was performed at T10 level. A balloon angioplasty catheter was inserted into the T9 level thoracic spinal cord extradurally. The rats were evaluated with the Tarlov Scale. After 24 hours, spinal cord tissues were taken for biochemical and histopathological examinations. TSCI effectuates unwanted results on tissues, antioxidant systems and cell membranes. Antioxidant enzyme level decreased and lipid peroxidation increased. However, TSCI led to inflammation and apoptosis. Glycyrrhizic acid treatment provided a significant decrease in lipid peroxidation in group III in comparison with group II. Moreover, nuclear respiratory factor 1 levels and superoxide dismutase activity of group III were significantly higher than group II ($p < 0.05$). The histopathological and immunohistochemical results revealed that the numbers of apoptotic and necrotic neuron, edema, hemorrhage, inflammatory cells, NF- κ B and S100B expressions were significantly lower than group II ($p < 0.05$). Our study showed that the glycyrrhizic acid treatment reduced oxidative stress and inflammation, and promoted the neuronal functions in traumatic spinal cord injury.

Key words: Traumatic spinal cord injury, glycyrrhizic acid, oxidative stress, apoptosis.

Introduction

Spinal cord injury affects the lives of both patients and their relatives. Not only voluntary motor, sensory, neurological and sexual function but also respiratory, gastrointestinal and cardiovascular systems of patients are affected by the location of the damage (1). A primary and a secondary mechanism play a role in spinal cord injury. While the primary injury occurs due to direct tissue trauma, the secondary results from bleeding and edema caused by vascular structure damage. Primarily the ischemia occurs in tissue and then the reperfusion injury is observed in the following days (2). The main objective of the treatment is to reduce edema and ischemia. For this purpose, steroids are widely used (3). Many drugs have been tried to eliminate post-ischemic reperfusion injury.

There is evidence that antioxidant polyphenols reduce cardiovascular disease and cancer risks thanks to their oxidative stress reducing properties. Therefore, they are typically described as chemopreventive agents (4). Owing to the discovery of the biological activities of these compounds in recent years, studies on flavonoids have become increasingly important (5). Glycyrrhizic acid (GA) isolated from *Glycyrrhiza glabra* (Licorice) root is a compound that has a flavonoid structure. Since the 4th century BC, licorice and its extracts have been used both for medical and culinary purposes. The root of the licorice plant known as 'sweet root' contains GA compound which is 50 times sweeter than common sugar (6). Salts of GA are widely used as flavor and sweetener in desserts, medicines, foods, chewing gums, chewing tobacco and toothpaste (7). High doses of GA have been shown to induce hypertension (8). However, various

pharmacological effects of GA have been reported such as anti-inflammatory (9, 10), neuroprotective (11), anti-viral (4), anti-allergic (12), anti-tumor (13), antioxidants (14) and hepatoprotective activity (15).

The aim of this study is to evaluate the effect of glycyrrhizic acid treatment on biochemical and histopathological changes in damaged spinal cord. The synthetic production of glycyrrhizic acid which has a wide range of uses is not currently performed; hence, plants which contain the GA compounds are the only source. The use of high dose of steroids is still a common practice to reduce the secondary damage in SCI. However, using glycyrrhizic acid instead of steroids with severe side effects would be useful to human health.

Materials and Methods

Animals and experimental design

Twenty four male Sprague-Dawley rats, weighing 250-300 g were obtained from Çanakkale Onsekiz Mart University Experimental Research Center (COMUDAM) and ethical permission was granted by Çanakkale Onsekiz Mart University Animal Experiment Local Ethics Committee (protocol number: 2014/13-7). The animals were allowed to access water and food *ad libitum*, before and after surgical procedure. 12-h

Received, March 9 2016; Accepted, April 2 2016; Published April 30 2016

* Corresponding author: Dr. Muserref Hilal Sehitoglu, Canakkale Onsekiz Mart University, Faculty of Medicine, Department of Medical Biochemistry, Canakkale, Turkey. Email: hill_al@hotmail.com

Copyright: © 2016 by the C.M.B. Association. All rights reserved.

darkness and 12-h light environment was provided with photoperiodic white fluorescent light. For appropriate conditions the temperature and humidity were adjusted $24\pm 1^\circ\text{C}$ and 55-60%, respectively. Rats were randomly divided into three groups and each groups consist eight rats. Group I: Sham operated group, drugs and presurgical procedures were not implemented to rats. Group II: Traumatic spinal cord injury group, spinal cord injury was administered for 5 minutes then rats were sacrificed after 24 hours reperfusion. Group III: Glycyrrhizic acid treatment group, spinal cord injury was applied for 5 minutes, then glycyrrhizic acid (single dose of 80 mg/kg body weight, intraperitoneal) was administered to rats. Rats were sacrificed after 24 hours reperfusion. All animal experiment methods for biomedical research were performed according to the international guiding principles recommended by WHO.

Dosage

The dosage was determined as 80 mg/kg body weight based on preliminary studies with various doses (10, 50, 75, 100 mg) to reveal the biological effects of glycyrrhizic acid (GA) (16, 17).

Surgical procedure

Spinal cord injury was carried out by the method described by Aslan and his colleagues (18). Rats were anesthetized by xylazine (5 mg/kg; Bayer, Istanbul, Turkey) and ketamine hydrochloride (50 mg/kg; Parke Davis, Istanbul, Turkey) with spontaneous breathing room air. The rats were fixed in the prone position on the operating table. The midline dorsal incision was made under sterile conditions. Laminated and the transverse processes between T6-L2 were seen through the blunt dissection of the paravertebral muscles. An automatic retractor was placed in the operation field and then, total laminectomy was performed at T10 level. A balloon angioplasty catheter (Simpass-PS12510-T, 1.25x10 mm, Istanbul, Turkey) was inserted until T9 level thoracic spinal cord as sublaminal to the extradural region. Blowing was slowly continued until it reaches up to 2 atm and then the pressure was maintained at 2 atm for 5 minutes. After the balloon catheter withdrawn carefully, paravertebral fascia and skin was sutured with 3/0 silk. The purpose of the application of balloon compression model is to create partial spinal cord lesion. After the trauma, SCI group rats were given 1 ml of saline, immediately. A single-dose of glycyrrhizic acid (80 mg/kg, i.p) was applied to GA group rats after SCI. After the medical treatment, rats were housed in their home cage for 24 hours and the neurological conditions were followed according to the Tarlov scale (19). Spinal cord tissue was removed at 24 hours with T8-T10 total laminectomy by opening the same wounds of the rats. Spinal cord of rats were divided into two equal parts and the first half was placed in a -80°C refrigerator for biochemical assays. The other half was stored in 4% formaldehyde solution for histopathological examination. At the end of this procedure the rats were sacrificed by deep anesthesia.

Histopathological examination

Hematoxylin & eosin and cresyl violet staining

All the samples were fixed in 10% neutral buffe-

red formalin and after dehydration in graded alcohols, samples were embedded in paraffin. 5 micron sections were obtained and mounted on normal and poly-L-lysine-coated slides. Hematoxylin & eosin (H&E) and Cresyl violet stainings were performed. For cresyl violet staining the sections were deparaffinized, rehydrated and rinsed with distilled water and then stained with 0.1 % cresyl violet for 8 minutes, following 95% and absolute ethanol dehydration, slides were cleared in xylene and mounted with entellan. Edema, hemorrhage and inflammatory cell migration were investigated for each group after H&E and cresyl violet stainings and scored semiquantatively as follows: 0 = normal, 1 = mild, 2 = moderate, and 3 = severe, respectively. At the same time, apoptotic and necrotic motor neurons in the gray matter were counted under 20x magnification. Motor neuron demonstrating disruption of cell nucleus and cytoplasm was accepted as a necrotic, neurons with condensed and darkening cytoplasm were regarded as apoptotic cells.

Immunohistochemistry of NF- κ B and S100B

Sections taken to poly-L-lysine coated slides, firstly deparaffinized and hydrated. Antigen retrieval was applied in microwave by heating in citrate buffer (pH=6.0) for 25 min. 3% hydrogen peroxidase in methanol was used for 13 min to eliminate endogenous peroxidase activity. After blocking with Ultra V Block solution, without washing, the sections were incubated with NF- κ B p65 (1:100 dilution, anti-NF- κ B p65 antibody, sc109, santa cruz biotechnology) and S100B (1:100, SH-B1, MA1-25004, Thermo Scientific) primary antibodies at 4°C overnight. After several washes in Tris-buffered saline (TBS) Tween 20, sections were incubated with biotinylated secondary antibody (Anti-polyvalent HRP, Labvision Corp, Fremont, CA) according to the manufacturer's protocol. Finally, sections were visualized by AEC kit (Labvision Corp, Fremont, CA) for the chromogen and then rinsed in distilled water and counterstained with a Mayer's hematoxylin for 1 min, and mounted with water based mounting medium. All the stained sections were examined under a microscope (Eclipse E-600 Nikon, Japan) and NF- κ B and S100B positive stained cells were counted in the gray matter of the section and captured under 20x with an image analysis system (NIS Elements Nikon, Japan). The data were statistically analyzed.

Statistical analysis

Measurement data are expressed as the mean \pm SD and analyzed using SPSS 21.0 software. p value <0.05 was considered statistically significant. Kruskal Wallis test was used to analyze the apoptotic, necrotic and immunostaining differences between the groups. Iman Conover test was used for pairwise comparisons. For edema, hemorrhage, inflammatory cell migration Chi Square Test was applied.

Biochemical investigations of spinal cord tissues

Rat tissues kept at -80°C were homogenized in a suitable buffer required by each methods. Each obtained supernatant was used for biochemical investigations of malondialdehyde (MDA), nuclear respiratory factory-1 (NRF1) levels and superoxide dismutase (SOD) activi-

ty. Measurements were realized in duplicate with highly sensitive ELISA spectrophotometry, respectively. The protein concentrations were determined by the Bradford method using Bradford reagent (Sigma Aldrich, Bradford reagent-B6916-1KT, USA). All the data was defined as the mean \pm standard deviation (SD) results based on per mg of protein.

Nuclear respiratory factor-1 (NRF1) assay principles

Rat nuclear respiratory factor 1 (NRF1) ELISA kit (Hangzhou Eastbiopharm CO., LTD., China) was used to assay NRF1 on the basis of the Biotin double antibody sandwich technology. Absorbances of each well were measured under 450 nm wavelength. The results were expressed as ng/ml NRF1 per milligram protein ($\text{ng}\cdot\text{ml}^{-1}\cdot\text{mg protein}^{-1}$).

Superoxide dismutase (SOD) activity assay principles

Tissue SOD activity was measured with SOD assay kit (Sigma-Aldrich-19160-St. Louis, MO, USA) using highly sensitive ELISA spectrophotometry. The IC50 (50% inhibition activity of SOD) values was determined by this colometric method under 450 nm. The results were expressed as U/ml SOD per milligram protein ($\text{U}\cdot\text{ml}^{-1}\cdot\text{mg protein}^{-1}$).

Lipid peroxidation (MDA) assay principles

Lipid peroxidation is determined by the reaction of malondialdehyde (MDA) with thiobarbituric acid (TBA) to form a colorimetric (532 nm) product, proportional to the MDA present. Lipid peroxidation (MDA) assay kit (Sigma-Aldrich-MAK085- St. Louis, MO, USA)

was used for determining MDA levels. The results were expressed as nmole/ml MDA per milligram protein ($\text{nmole}\cdot\text{ml}^{-1}\cdot\text{mg protein}^{-1}$).

Statistical Analysis

Results were subjected to one-way analysis of variance (ANOVA) using SPSS 21.0 software (SPSS Inc., USA). Differences among the groups were obtained using Tukey's test option. Statistical significance was accepted as $p < 0.05$. All data was expressed as mean \pm standard deviation (SD) in each group.

Results

H&E and cresyl violet stainings results

According to the H&E and cresyl violet stainings neuronal and vascular structures were assessed in normal morphology in the control group (Figure 1A-2A). In injury group, widespread hemorrhage and generalized edema in gray matter were observed and increase in infiltrative cell migration were prominent (Figure 1B). In addition to; apoptotic and necrotic cells were profoundly observed (Figure 2B) in the gray matter. Cord damage and tissue loss especially were observed over the dorsal and lateral sides of the spinal cord. Cavitation areas were also observed. Glycyrrhizic acid treatment partially protected neurons from the injury. The number of necrotic and apoptotic was declined in the glycyrrhizic acid group compared to injury group and hemorrhage, edema and inflammatory cell migration significantly lower than injury group ($p < 0.05$) and cavitation areas were present (Figure 1C-2C).

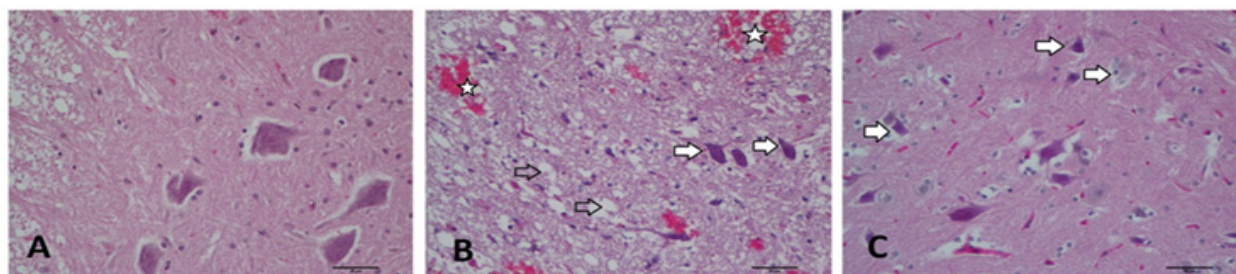


Figure 1. Representative sections of spinal cords in gray matter stained with H&E (X200, scale bar = 50 μm). Normal neurons exhibited a fine granular cytoplasm, while degenerated neurons were defined by the presence of cytoplasmic shrinkage with a diffuse cytoplasm. (A) Control group: showing normal parenchyma and viable neurons (B) Injury group: showing hemorrhage (asterisk) and apoptotic neurons with shrunken cytoplasm and darkly stained of cytoplasm (arrows) and cavitation areas (hollow arrows) in the gray matter. (C) Glycyrrhizic acid group showing less hemorrhage and motor neurons less affected than ischemic injury (arrows).

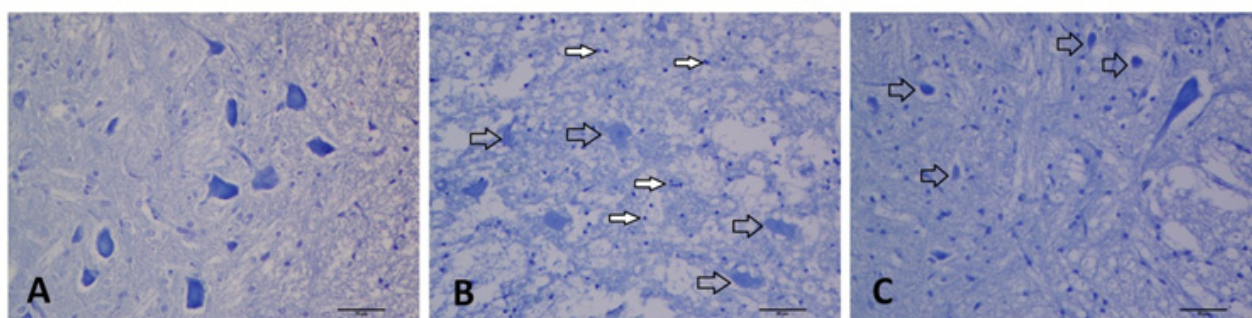


Figure 2. Representative cresyl violet stained sections from the experimental groups (X200, scale bar = 50 μm). (A) In the control group, motor neurons showed regular nuclei lightly stained, and Nissl bodies in the cytoplasm. (B) In the injury group, necrotic cells consistent with the surrounding tissue infarcts are prominent (hollow arrows) and filled arrows indicate increased number of inflammatory cells. (C) Glycyrrhizic acid group showed less infarct area and neurons affected from injury (hollow arrows).

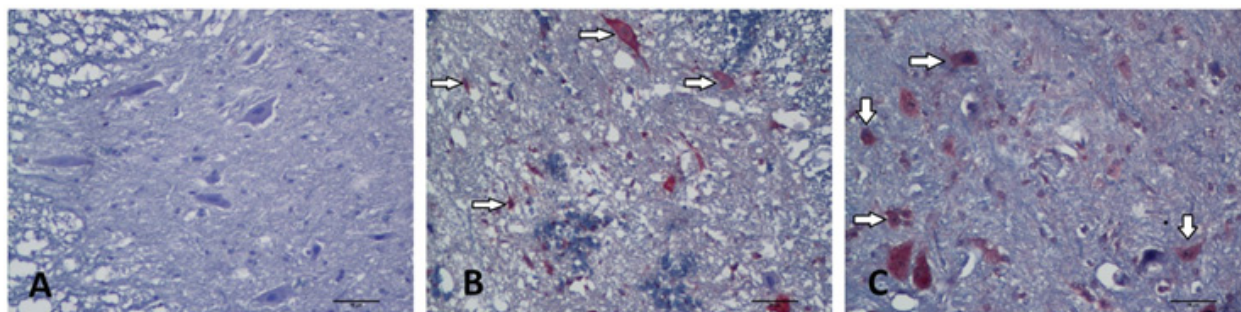


Figure 3. Representative images of NF-κB immunostaining in the experimental groups (X200, scale bar = 50 μm). Arrows refer to NF-κB positivity (A) In the control group, neurons showed few NF-κB staining. (B) In the injury group, significantly increased number of NF-κB positivity were observed in neurons compared to controls. (C) NF-κB positivity were visible in some neurons in the glycyrrhizic acid group but the number of NF-κB positive cells was lower than that in the injury group.

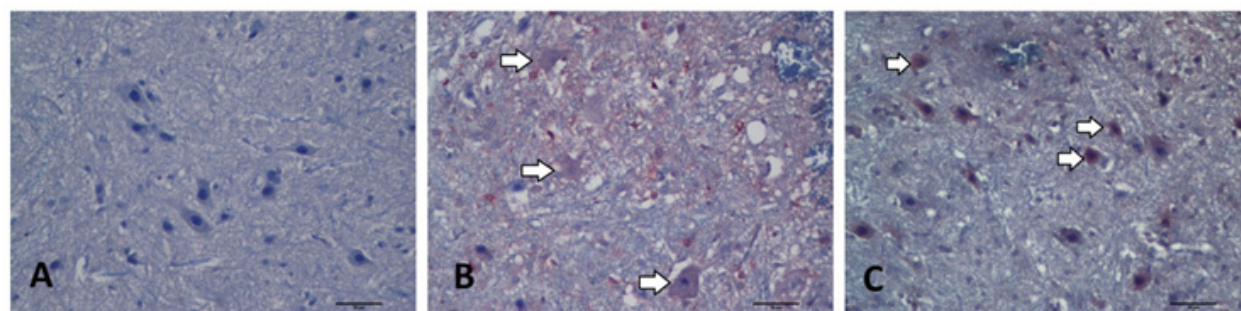


Figure 4. Representative images of S100B immunostaining in the experimental groups (X200, scale bar = 50 μm). (A) No positivity were observed in the control group. (B) Injury group revealed increased S100B positivity in apoptotic and necrotic motor neurons (C) Glycyrrhizic acid group revealed less S100B immunopositivity than injury group.

Table 1. Histopathological evaluation of the stainings belong to experimental groups. The values are presented as mean±SD. In each line, the difference between the means with the same letters are significant ($p < 0.05$) (for edema, hemorrhage, inflammatory cell migration Chi Square Test, for the others Iman Conover Test were applied).

	Groups		
	Control	SC Injury	Glycyrrhizic acid
Apoptotic neuron number	0.50±0.75 ^{a,b}	27.50±3.33 ^a	19.63±4.06 ^b
Necrotic neuron number	0.00±0.00 ^{a,b}	17.25±6.22 ^a	14.38±3.15 ^b
Edema	0.13±0.35 ^{a,b}	2.75±0.46 ^{a,c}	2.25±0.46 ^{b,c}
Hemorrhage	0.00±0.00 ^{a,b}	2.88±0.35 ^{a,c}	2.38±0.51 ^{b,c}
Inflammatory cell migration	0.00±0.00 ^{a,b}	2.75±0.46 ^{a,c}	2.13±0.35 ^{b,c}
NF-κB Expression	2.75±1.03 ^{a,b}	50.75±9.49 ^a	45.00±7.32 ^b
S100B Expression	1.88±2.10 ^{a,b}	51.25±6.22 ^a	41.88±11.63 ^b

NF-κB and S100B immunohistochemistry

By NF-κB and S100B immunostainings, rare positive cells were observed in the control group (Figure 3A-4A, respectively). NF-κB (Figure 3B) and S100B (Figure 4B) expressions were increased in the neurons after injury and statistically significant compared with the controls. NF-κB (Figure 3C) and S100B (Figure 3D) positivity in neurons were observed diminished in the glycyrrhizic acid group compared with the injury group but this decrease was not statistically significant (Figure 3C) ($p > 0.05$).

Biochemical results

The mean and standard deviation values of NRF1, SOD and MDA in each group were given in Table 4 and Figure 5. NRF1 levels of injury group were found to be lower compared to the other groups and this was statistically significant ($p < 0.05$). There was a significant difference between glycyrrhizic acid group and injury

group ($p < 0.05$). It was seen that NRF 1 levels of glycyrrhizic acid group almost reached the control group's (Figure 5A). SOD activities of glycyrrhizic acid group were significantly different compared to the injury group ($p < 0.05$) (Figure 5B). There was no statictically difference between glycyrrhizic acid and control groups ($p > 0.05$) but it was quite significant. MDA levels of injury group were found to be significantly higher than other groups and glycyrrhizic acid group was statistically significant compared to injury and control group ($p < 0.05$) (Figure 5C).

Discussion

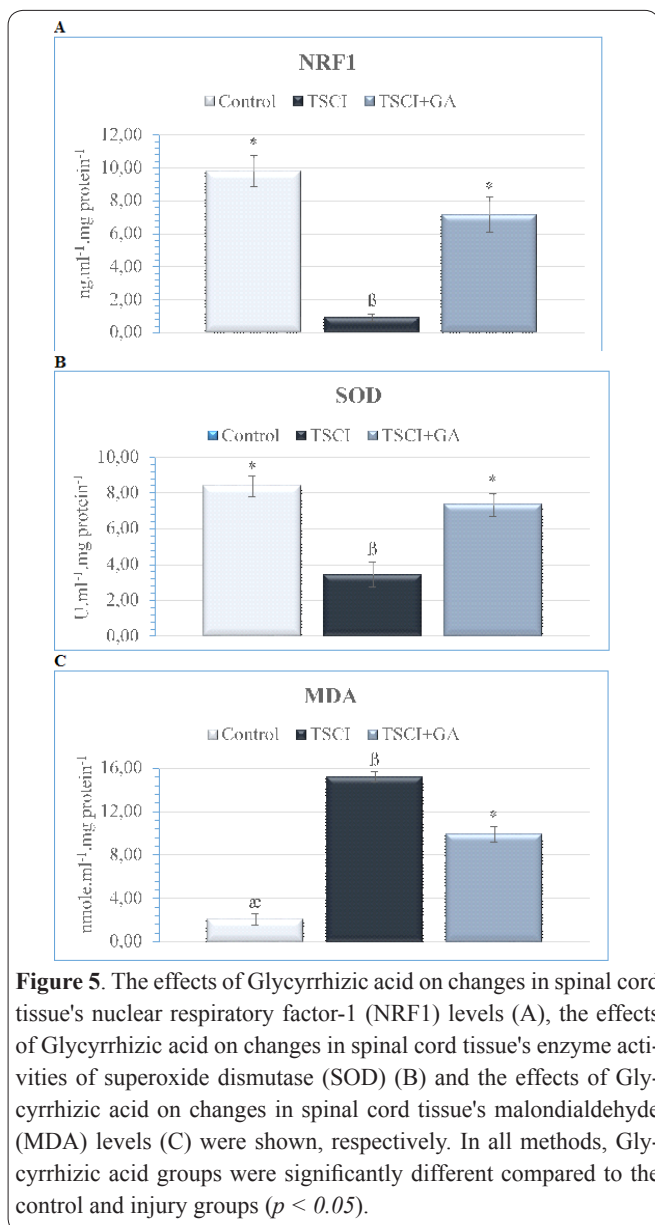
A hydroxyl group bonded directly to an aromatic hydrocarbon group (-OH) causes the structure to have an antioxidant property. Polyphenolic compounds containing multiple hydroxyl groups in their structures have been suggested to scavenge reactive oxygen species

Table 2. P values of pairwise comparisons between the groups (I : control group, II : Traumatic spinal cord injury group, III : Glycyrrhizic acid group).

Groups	Apoptotic neuron number	Necrotic neuron number	Edema	Hemorrhage	Inflammatory cell migration
I-II	0.000	0.000	0.001	0.000	0.000
I-III	0.015	0.001	0.001	0.000	0.000
II-III	0.051	0.564	0.046	0.039	0.012

Table 3. P values of pairwise comparisons between the groups (I : control group, II : Traumatic spinal cord injury, III : Glycyrrhizic acid group).

Groups	NF- κ B Expression	S100B Expression
I-II	0.000	0.000
I-III	0.002	0.005
II-III	0.479	0.215

**Figure 5.** The effects of Glycyrrhizic acid on changes in spinal cord tissue's nuclear respiratory factor-1 (NRF1) levels (A), the effects of Glycyrrhizic acid on changes in spinal cord tissue's enzyme activities of superoxide dismutase (SOD) (B) and the effects of Glycyrrhizic acid on changes in spinal cord tissue's malondialdehyde (MDA) levels (C) were shown, respectively. In all methods, Glycyrrhizic acid groups were significantly different compared to the control and injury groups ($p < 0.05$).

(ROS) because of their antioxidative functions (20). ROS caused by oxidative stress plays an important role in the pathogenesis of traumatic SCI as in many diseases (21, 22). The amount of superoxide, hydroxyl and hydrogen peroxide radicals rapidly increase after trauma (23, 24). The present study emphasizes the role of glycyrrhizic acid in remedying oxidative stress and inflammation on traumatic spinal cord injury. We biochemically and histopathologically observed an important increase in oxidative stress resulting from ROS during SCI. It is known that the NF- κ B activation increases in spinal cord injury and is an important indicator in major neurodegenerative diseases. NF- κ B is a kind of transcription factor and regulates pro-inflammatory cytokine expression (25, 26, 27). Inflammatory cytokine expression increases with traumatic spinal cord injury (28). In this study, decreasing inflammatory cell migration in glycyrrhizic acid group according to SCI group provides evidence for anti-inflammatory effect of glycyrrhizic acid (Table 1, Figure 1). We showed the anti-inflammatory effect of glycyrrhizic acid which has a down regulating NF- κ B function (Table 1, Figure 3) (29). High levels of ROS can lead to lipid peroxidation, oxidative chain reactions, and damage to cellular macromolecules resulting in death of host neurons and glia (30). Glycyrrhizic acid group exhibited less edema and hemorrhage than SCI group did, and further motor neurons were less affected in the former (Table 1, Figure 1 and Figure 2). The neuroprotective effect of glycyrrhizin and its derivatives has been reported in previous studies (31, 32, 33). High levels of ROS like those found in the injured spinal cord may lead to cell death (26). It was seen that the cell death of glycyrrhizic acid treated SCI rats decreased in comparison with the spinal cord injury group (Table 1, Figure 2). In the present findings, reduction in apoptotic and necrotic neurons of glycyrrhizic acid treatment hints the inhibitory effect of glycyrrhizic acid on neutrophil infiltration and it may prove beneficial against SCI-induced oxidative stress due to its protective effect.

S100B is an important peripheral biomarker of blood-barrier permeability secreted by astrocytes or can spill from injured cells. Neuropathological conditions including traumatic head injury or neurodegenerative diseases are characterized by elevated S100B levels (34). We found that S100B expression level was higher

Table 4. The activity of superoxide dismutase (SOD), levels of malondialdehyde (MDA) and nuclear respiratory factor-1 (NRF1) of rat spinal cord tissues.

Groups	NRF1 (ng.ml ⁻¹ .mg protein ⁻¹)	SOD (U.ml ⁻¹ .mg protein ⁻¹)	MDA (nmole.ml ⁻¹ .mg protein ⁻¹)
Control	9.79 ± 0.93 *	8.38 ± 0.56 *	2.09 ± 0.52 ^α
TSCI	0.90 ± 0.22 ^β	3.43 ± 0.69 ^β	15.21 ± 0.50 ^β
TSCI + GA	7.14 ± 1.07 *	7.33 ± 0.62 *	9.90 ± 0.70 *

Note: TSCI; Traumatic spinal cord injury, GA; Glycyrrhizic acid. Means in the same column by the different letter are significantly different compared to each other according to the One-way ANOVA-Tukey's test. ($p < 0.05$). Data was expressed as mean ± SD.

in neurons in SCI group rats ($p < 0.05$). However, glycyrrhizic acid treatment group revealed less S100B immunopositivity than injury group (Table 1, Figure 4).

Studies have demonstrated that oxidative stress markers increase during spinal cord injury. This excessive production of reactive oxygen species damages cell membranes. Membrane lipids undergoes peroxidation and produce malondialdehyde (MDA) (35). Previous studies have also demonstrated that MDA has significantly increased in animals exposed to traumatic SCI (18, 36). Neural tissues are quite sensitive after SCI and easily affected by lipid peroxidation. In our study we showed the effect of pre-treating glycyrrhizic acid on MDA levels in SCI. There was a statistically significant difference in MDA levels between glycyrrhizic acid and SCI groups ($p < 0.05$) (Table 4, Figure 5C). Superoxide anion radical ($O_2^{\cdot-}$) induces tissue damage with reacting biological macromolecules such as carbohydrates, proteins, enzymes, lipids or DNA by leading to the production of other free radicals and it has been determined to induce lipid peroxidation (37, 38). Superoxide dismutase is responsible for transformation of superoxide anion into H_2O_2 . H_2O_2 treatment constantly results in the production of ROS. The resultant superoxide anion radicals are eliminated by the enhanced SOD activity for lessening H_2O_2 -induced damage (39). We observed a significant difference in SOD activities of glycyrrhizic acid group compared to SCI group ($p < 0.05$) (Figure 5B). Although we found that SOD activity was elevated following glycyrrhizic acid treatment, glycyrrhizic acid had a potent effect on enhancing SOD activity. Therefore, the use of glycyrrhizic acid can be suggested to protect from H_2O_2 -induced oxidative stress.

Mechanisms underlying neuroprotection may include attenuation of pro-inflammatory reactions, brain edema, blood-brain barrier damage, and cognitive and behavioral deficits. NRF1, which helps neuroprotection, is a transcription factor responsible for regulating mitochondrial biogenesis (40). In our previous studies we have demonstrated that NRF1 levels of ischemia-reperfusion-induced spinal cord injury were quite lower than in healthy rats (41, 42). Glycyrrhizic acid treatment was also found to increase NRF1 level (Table 4, Figure 5A).

In conclusion, our study demonstrated anti-inflammatory and anti-oxidative neuroprotection effects of glycyrrhizic acid. Previous studies support our study, but future studies can investigate dose-dependent glycyrrhizic acid treatment results on long-term traumatic spinal cord injury. We could suggest that dietary supplement containing glycyrrhizic acid may be useful to prevent SCI.

References

- Kavakli HS, Koca C, Alici O. Antioxidant effects of curcumin in spinal cord injury in rats. *Ulus Travma Acil Cerrahi Derg* 2011; 17: 14-18.
- Ersahin M, Toklu HZ, Erzik C, Akakin D, Tetik S, Sener G, Yegen BC. Ghrelin alleviates spinal cord injury in rats via its anti-inflammatory effects. *Turk Neurosurg* 2011; 21: 599-605.
- Hugenholtz H, Cass DE, Dvorak MF, Fewer DH, Fox RJ, Izukawa DM, Lexchin J, Tuli S, Bharatwal N, Short C. High-dose methylprednisolone for acute closed spinal cord injury only a treatment option. *Can J Neurol Sci* 2002; 29: 227-235.
- Arts IC, Hollman PC. Polyphenols and disease risk in epidemiologic studies. *Am J Clin Nutr* 2005; 81: 317-325.
- Kabra DG, Thiyagarajan M, Kaul CL, Sharma SS. Neuroprotective effect of 4-amino-1,8-naphthalimide, a poly(ADP ribose) polymerase inhibitor in middle cerebral artery occlusion-induced focal cerebral ischemia in rat. *Brain Res Bull* 2004; 62: 425-433.
- Armanini D, De Palo CB, Mattarello MJ, Spinella P, Zaccaria M, Ermolao A, Palermo M, Fiore C, Sartorato P, Francini-Pesenti F, Karbowski I. Effect of licorice on the reduction of body fat mass in healthy subjects. *J Endocrinol Invest* 2003; 26: 646-650.
- Fenwick GR, Lutowski J, Nieman C. Licorice, *Glycyrrhiza glabra* L. Composition, uses and analysis. *Food Chem* 1990; 38: 119-143.
- Ma SK, Bae EH, Kim IJ, Choi KC, Kim SH, Lee J, Kim SW. Increased renal expression of nitric oxide synthase and atrial natriuretic peptide in rats with glycyrrhizic-acid-induced hypertension. *Phytother Res* 2009; 23: 206-211.
- Barone FC, Feuerstein GZ. Inflammatory mediators and stroke: new opportunities for novel therapeutics. *J Cereb Blood Flow Metab* 1999; 19: 819-834.
- Racková L, Jancinová V, Petriková M, Drábiková K, Nosál R, Stefek M, Kostálová D, Prónayová N, Kováčová M. Mechanism of anti-inflammatory action of licorice extract and glycyrrhizin. *Nat Prod Res* 2007; 21: 1234-1241.
- Kim SW, Jin Y, Shin JH, Kim ID, Lee HK, Park S, Han PL, Lee JK. Glycyrrhizic acid affords robust neuroprotection in the postischemic brain via anti-inflammatory effect by inhibiting HMGB1 phosphorylation and secretion. *Neurobiol Dis* 2012; 46: 147-156.
- Park HY, Park SH, Yoon HK, Han MJ, Kim DH. Anti-allergic activity of 18beta-glycyrrhetinic acid-3-O-beta-D-glucuronide. *Arch Pharm Res* 2004; 27: 57-60.
- Smolareczyk R, Cichon T, Matuszczak S, Mitrus I, Lesiak M, Kobusińska M, Kamysz W, Jarosz M, Sieroń A, Szala S. The role of Glycyrrhizin, an inhibitor of HMGB1 protein, in anticancer therapy. *Arch Immunol Ther Exp (Warsz)* 2012; 60: 391-399.
- Li XL, Zhou AG, Zhang L, Chen WJ. Antioxidant status and immune activity of glycyrrhizin in allergic rhinitis mice. *Int J Mol Sci* 2011; 12: 905-916.
- Orazizadeh M, Fakhredini F, Mansouri E, Khorsandi L. Effect of glycyrrhizic acid on titanium dioxide nanoparticles-induced hepatotoxicity in rats. *Chem Biol Interact* 2014; 220: 214-221.
- Rasool M, Iqbal J, Malik A, Ramzan HS, Qureshi MS, Asif M, Qazi MH, Kamal MA, Chaudhary AG, Al-Qahtani MH, Gan SH, Karim S. Hepatoprotective Effects of *Silybum marianum* (Silymarin) and *Glycyrrhiza glabra* (Glycyrrhizin) in Combination: A Possible Synergy. *Evid Based Complement Alternat Med* 2014; 2014: 641597.
- Fakhari S, Abdolmohammadi K, Panahi Y, Nikkhoo B, Peirmohammadi H, Rahmani MR, Moghadam AS, Jalili A. Glycyrrhizin attenuates tissue injury and reduces neutrophil accumulation in experimental acute pancreatitis. *Int J Clin Exp Pathol* 2014; 7: 101-109.
- Aslan A, Cemek M, Eser O, Altunbas K, Buyukokuroglu ME, Cosar M, Bas O, Ela Y, Fidan H. Does dexmedetomidine reduce secondary damage after spinal cord injury? An experimental study. *Eur Spine J* 2009; 18: 336-344.
- Tarlov IM, and Klinger H. Spinal cord compression studies: II. Time limits for recovery after acute compression in dogs. *AMA Arch Neurol Psychiatry* 1954; 71: 271-290.
- Şehitoğlu H, Han H, Kalın P, Gülçin İ, Özkan A, Aboul-Enein HY. Pistachio (*Pistacia Vera* L.) Gum: A Potent Inhibitor Of Reactive Oxygen Species. *J Enzyme Inhib Med Chem* 2015; 30: 264-269.
- Tator CH, Fehlings MG. Review of the secondary injury theory of acute spinal cord trauma with emphasis on vascular mechanisms. *J Neurosurg* 1991; 75: 15-26.

22. Anderson DK, Hall ED. Pathophysiology of spinal cord trauma. *Ann Emerg Med* 1993; 22: 987-992.
23. Liu D, Liu J, Sun D, Wen J. The time course of hydroxyl radical formation following spinal cord injury: the possible role of the iron-catalyzed Haber-Weiss reaction. *J Neurotrauma* 2004; 21: 805-816.
24. Xu W, Chi L, Xu R, Ke Y, Luo C, Cai J, Qiu M, Gozal D, Liu R. Increased production of reactive oxygen species contributes to motor neuron death in a compression Mouse model of spinal cord injury. *Spinal Cord* 2005; 43: 204-213.
25. Kopitar-Jerala N. Innate Immune Response in Brain, NF-Kappa B Signaling and Cystatins. *Front Mol Neurosci* 2015; 8: 73.
26. Wang W, Shen H, Xie JJ, Ling J, Lu H. Neuroprotective effect of ginseng against spinal cord injury induced oxidative stress and inflammatory responses. *Int J Clin Exp Med* 2015; 8: 3514-3521.
27. Ni B, Cao Z, Liu Y. Glycyrrhizin protects spinal cord and reduces inflammation in spinal cord ischemia-reperfusion injury. *Int J Neurosci* 2013; 123: 745-751.
28. Zhang C, Ma J, Fan L, Zou Y, Dang X, Wang K, Song J. Neuroprotective effects of safranal in a rat model of traumatic injury to the spinal cord by anti-apoptotic, anti-inflammatory and edema-attenuating. *Tissue Cell* 2015; 47: 291-300.
29. Gao Y, Hao J, Zhang H, Qian G, Jiang R, Hu J, Wang J, Lei Z, Zhao G. Protective effect of the combinations of glycyrrhizic, ferulic and cinnamic acid pretreatment on myocardial ischemia-reperfusion injury in rats. *Exp Ther Med* 2015; 9: 435-445.
30. Hall ED. Antioxidant therapies for acute spinal cord injury. *Neurotherapeutics* 2011; 8: 152-167.
31. Akman T, Guven M, Aras AB, Ozkan A, Sen HM, Okuyucu A, Kalkan Y, Sehitoglu I, Silan C, Cosar M. The neuroprotective effect of glycyrrhizic acid on an experimental model of focal cerebral ischemia in rats. *Inflammation* 2015; 38: 1581-1588.
32. Hou SZ, Li Y, Zhu XL, Wang ZY, Wang X, Xu Y. Ameliorative effects of diamonium glycyrrhizinate on inflammation in focal cerebral ischemia-reperfusion injury. *Brain Res* 2012; 1447: 20-27.
33. Gong G, Xiang L, Yuan L, Hu L, Wu W, Cai L, Yin L, Dong H. Protective effect of glycyrrhizin, a direct HMGB1 inhibitor, on focal cerebral ischemia-reperfusion-induced inflammation, oxidative stress and apoptosis in rats. *PLoS One* 2014; 9: e89450.
34. Michetti F, Corvino V, Geloso MC, Lattanzi W, Bernardini C, Serpero L, Gazzolo D. The S100B protein in biological fluids: more than a lifelong biomarker of brain distress. *J Neurochem* 2012; 120: 644-659.
35. Cheeseman KH, Slatter TF. An introduction to free radical biochemistry. *Br Med Bull* 1993; 49: 481-493.
36. Ates O, Cayli SR, Gurses I, Turkoz Y, Tarim O, Cakir CO, Kocak A. Comparative neuroprotective effect of sodium channel blockers after experimental spinal cord injury. *J Clin Neurosci* 2007; 14: 658-665.
37. Halliwell B, Gutteridge JMC. Oxygen toxicology, oxygen radicals, transition metals and disease. *Biochem J* 1984; 219: 1-4.
38. Wickens AP. Aging and the free radical theory. *Resp Physiol* 2001; 128: 379-391.
39. Ryter SW, Kim HP, Hoetzel A, Park JW, Nakahira K, Wang X, Choi AM. Mechanisms of cell death in oxidative stress. *Antioxid Redox Signal* 2007; 9: 49-89.
40. Zhang Q, Wu Y, Sha H, Zhang P, Jia J, Hu Y, Zhu J. Early Exercise Affects Mitochondrial Transcription Factors Expression after Cerebral Ischemia in Rats. *Int J Mol Sci* 2012; 13: 1670-1679.
41. Guven M, Sehitoglu MH, Yuksel Y, Tokmak M, Aras AB, Akman T, Golge UH, Karavelioglu E, Bal E, Cosar M. The Neuroprotective Effect of Coumaric Acid on Spinal Cord Ischemia/Reperfusion Injury in Rats. *Inflammation* 2015; 38: 1986-1995.
42. Tokmak M, Yuksel Y, Sehitoglu MH, Guven M, Akman T, Aras AB, Cosar M, Abbed KM. The Neuroprotective Effect of Syringic Acid on Spinal Cord Ischemia/Reperfusion Injury in Rats. *Inflammation* 2015; 38: 1969-1978.